

Dens Invaginatus: Literature Review

Shama Asghar

Abstract:

Dens invaginatus is a developmental malformation of the tooth germ which originates as a result of the infolding of the enamel organ. It has been expressed as a 'tooth within a tooth' or 'dens in dent' or as an invagination of an enamel-lined tract extending into the root at a various depth, with or without involvement of the dental pulp. Search engines as Pak-Medinet, Pub Med, Medline and Google scholar were used to search literature about this abnormality. Dens invaginatus has complicated root canal morphology and the etiology of this developmental abnormality is still ambiguous. Possible causes include trauma, infection, development retardation of specific cells, interruption in factors regulating the development of enamel organ, and associations to genetic factors. Clinical features, radiological findings (periapical, occlusal radiograph, 3-dimensional imaging system CBCT) and surgical operating microscope help the clinician in classifying the morphology of the dens so that correct treatment planning and management alternative can be chosen. The treatments choices consist of; preventive sealing, restoration of the invagination, endodontic management, apical curettage and surgical endodontic, planned replantation and removal of tooth.

Keywords: Dens invaginatus, Dens in dent, Developmental abnormality, Trauma, Infection, Radiographic features, Pulp necrosis.

INTRODUCTION:

Dens invaginatus (DI) is a developmental dental abnormality resulting from an infolding of enamel organ into the dental papilla before calcification of the hard tissues occurs.^{1,2,3} The beginning of this infolding can be different, it may extend only to the amelo-cemental junction, penetrate into the pulp cavity, to severe type in which the invagination extends into the root and occasionally reach to the root apex with a second opening.^{2,4}

Ploquet first described this type of abnormality in a Whales' tooth in 1794.⁵ Socrates described a case of Dens invaginatus in human tooth in 1856.⁶ Tomes illustrated this kind of anomalous in his textbook in 1887.⁷ Hallet used the word dens invaginatus for this malformation to explain enamel is present centrally and the dentine peripherally due to the invagination.⁸ Salter first recommended the term "a tooth within a tooth" for this abnormality in 1855 and Busch first used of 'dens in dente' termin 1897.⁹ Hunter in 1951 introduced the term 'dilated composite odontome' that concludes an anomalous dilatation of the dental papilla at the same time as Colby suggested the term or gestant abnormality' for dense invaginatus.¹⁰ Of the different names 'dens invaginatus' would appear to be the more suitable

because it revealed the invagination of the external part (enamel) into the internal part (dentin) with the development of a pouch and dead space.¹¹ (Table 1) This review article highlights the etiology, incidence, classification, clinical and radiographic features along with various treatment alternatives.

Table 1

Other synonyms used to express Dens Invaginatus

- Dense in dente
- Invaginate odontome
- Dentoid in dente
- Tooth inclusion.
- Dilated gestant odontome
- Dilated composite odontome
- Dents telescopes
- Telescopic tooth

METHODOLOGY:

Following keywords and phrases (dense in dent, tooth within the tooth, theories of dense invaginatus, clinical and radiographic features of DI, treatment modalities of DI) were used on different search engines such as Google Search, Pak-medinet, Pub Med and Medline to search literature regarding this mal-development during the period of Jan 2013 to Dec 2013.

AETIOLOGY OF DENS INVAGINATUS:

1. Several theories have been presented over the last few decades to clarify the etiology of this malformation but it is still controversial.

✉ Dr. Shama Asghar
 Assistant Professor & Head Operative Dentistry Department
 Dental Section,
 Bahria University Medical and Dental College
 Karachi
 E-mail: shama.asghar@yahoo.com
 ✉ Dr. Farheen Fatima
 Lecturer, Operative Department
 Dental Section
 Bahria University Medical and Dental College
 Karachi.
 Received: March 19, 2014 Revised: May 21, 2014 Accepted: May 27, 2014

2. During development of the teeth, growth pressure on the dental arches will result in 'buckling' of the enamel organ leading to the invagination.⁵
3. At a certain point, the internal enamel epithelium fails to grow¹⁴
4. Rushton described that rapid proliferation of the inner enamel epithelium invading the dental papilla.¹⁵
5. Oehlers proposed that modification of the enamel organ take place at some stage in growth with extension of part of the enamel resulting to an enamel-lined canal finishing at the cingulum or the incisal tip.¹⁶
6. The 'twin-theory' described a cause of invagination is a joining together of two tooth germs.¹⁷
7. Infection¹⁸ and trauma.⁴
8. Hereditary factors.¹⁹
9. Ecto-mesenchymal signaling coordination between dental papilla and the inner enamel epithelium may influence tooth morphology and the folding of enamel organ.²⁰
10. Now the most accepted theory, it may possibly arise from a deep invagination of foramen caecum during tooth formation which in some cases can extend to form a second opening at apex.²¹

OCCURRENCE OF DENS INVAGINATUS:

Hovland reported the prevalence of Dens invaginatus to be varied from 0.04 to 10%.²² This anomaly usually involves permanent maxillary lateral incisors accounting for 42% of all cases, followed by maxillary central incisors, premolars, canines and less commonly in the molars.^{12,13}

Cakici et al described that DI was noticed in maxillary lateral incisors with no sex variation.²³ Mandibular teeth are also affected, although this is not as common as maxillary teeth.^{22,23} Bilateral occurrences accounting for 43% of cases and multiple incidence of have also been observed. Swanson and McCarthy reported about bilateral occurrence of invagination.²⁴ Deciduous dentition with this malformation has also been described in various studies¹³ in association with other dental abnormality, for example dentino- genesis imperfect and supernumerary teeth.^{13,20} By applying Oehlers' classification, Ridell et al reported in 2001 the prevalence of each kind of invagination, Type I was the most frequent (79%) while Type II (15%) and Type III (5%).²⁹

CLASSIFICATION:

The first classification of dens invaginatus was documented by Hallet in 1953 who recommended the presence of four kinds of infolding depending on both clinical and radiographic features.⁸ Others also classified²⁵ DI for example, Schulze and Brand in 1972 suggested a classification depending on twelve possible difference in clinical and radiographic features of the infolding.²⁶ The classification illustrated by Oehlers in 1957 shows to be the most commonly used, as it has simple nomenclature and easy to apply.¹⁶

Oehlers categorized dense invaginations (coronal invaginations (Figure 1) into three classes as depending on radiographic extension of enamel infolding inside the tooth.^{11,16}

TYPE I: The invagination or infolding of enamel organ is minimal and is restricted to the coronal portion of the tooth, not extending further than the cemento-enamel interface.^{5,6}

TYPE II: The invagination which invades the root extends beyond the cemento-enamel junction ends as a blind pouch. It confines within the root canal and may or may not communicate with the dental pulp.¹⁶

TYPE III (A): The infolding of enamel organ penetrates throughout the root and communicates with the periodontal ligament space through a pseudo-foramen. It has no contact with the dental pulp.^{5,11}

TYPE III (B): The invagination passes through the course of the root canal and communicates at the apical foramen with the periodontal ligament, giving rise to two or additional foramina. It may or may not communicate with the dental pulp.²⁷ In type III, any contamination inside the invagination give rise to a 'peri-invagination periodontitis'.¹ Oehlers in 1958, also explained the radicular type of infolding.²⁷ This kind is uncommon and occur secondary to a proliferation of Hertwig's root sheath and radio graphically the involved tooth revealed an enlargement of the root.²⁸ Schulze & Brand in 1972, proposed a comprehensive classification, comprising invaginations originating at the incisal edge of the tooth and also telling dysmorphic root configuration.²⁶ Bhaskar³⁰ classified Dens invaginatus into two kinds, (a) Coronal type and (b) Radicular type. (Table 2)

Figure 1
Oehler's classification of Dens invaginatus
Type I Type II Type III-A Type III-B

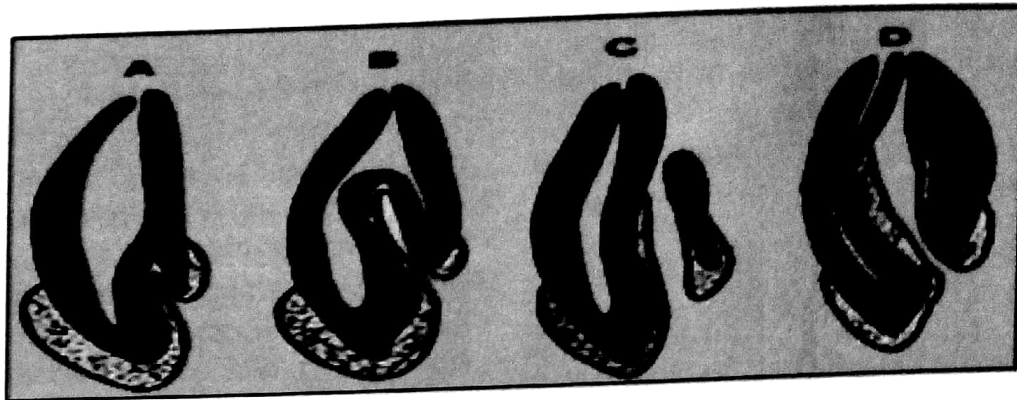


Table 2
Bhaskar³⁰ classified Dens Invaginatus into two types

Coronal type	It is occurred by an invagination of all layers of the enamel organ into the dental papilla. The pulp is generally exposed, necrotic or inflamed. Not uncommonly, periapical lesions are related with this type, endodontic therapy is required.
Radicular type	In this type, folding of Hertwig's sheath into the developing root and pulpal necrosis and periapical apical lesions are frequently there.

HISTOLOGICAL FINDINGS:

Histological examinations of this mal-developmental have showed contradictory results. Brabant and Klees⁶ in 1956, Omnell et al in 1960³¹, De Smit et al³² in 1984, Piatelli and Trisi³³ in 1993 described the infolded surface as being uniform and regular with no contact with the pulp. Kronfeld¹⁴ and others^{4,16} have observed disruption in the infolded surface which might provide gateway for irritants to the pulp.²⁷

Atkinson⁵ reported the structure of enamel was irregular while Baynon⁷ described hypomineralized enamel at the bottom of the invagination. Morfis noticed phosphate and calcium eight times more in the enamel lining of dense invaginatus as compared with the outer enamel.³⁴ Bloca-Zupan

et al found the internal enamel revealed more complicated rod appearances and its surface showed the distinctive honey comb prototype but no pen-kymata was seen on the external surface of tooth.³⁵ Kramer described irregularities in the composition of the enamel sheet of the infolding, with the safe and sound dentine. He explained that the deficiency of enamel in these parts allow direct entry of microbes into the dentine tubules and give rise pulpal infection.³⁶ The dentine beneath the invagination may be undamaged devoid of irregularities but Omnell et al³¹ and others^{2,5} also found irregular dentine surrounding the invagination.⁵

However, even though the limitations of various studies,^{5,32} the widely accepted observation is that

teeth influenced with this abnormality has high threat of developing pulpal crisis.¹³⁻¹⁷ This can take place without sign of any observable caries or history of trauma.¹⁷

DIAGNOSIS:

Often, teeth affected with Dens invaginatus do not exhibit any clinical signs of abnormality and hence cases may come to the dental surgeon as a consequence of the patient suffering from symptoms of pulpitis. In the majority cases, this abnormality is noticed accidentally on the radiograph. Clinical diagnosis, (1) the abnormal crown morphology (such as distended, hook or peg-shaped, barrel-shaped teeth) (2) a deep foramen caecum, can be significant clues.¹⁰ While maxillary lateral incisors are more prone to coronal infoldings, so these teeth should be examined carefully clinically and radiographically, especially in all cases in which a deep pit at the foramen caecum is present.^{7,8,9} If one tooth is involved in a patient the contralateral tooth should also be examined. Pulpal contamination of teeth with this mal-development may occur immediately after tooth eruption, thus early identification is compulsory to initiate precautionary management.^{2,6,31,34} Conventional radiograph cannot give comprehensive structural information regarding this abnormality. Newest radiographic technology (CBCT, spiral computed tomography) which are not only useful in identification of dens invaginatus but also provide three-dimensional picture of the root canal anatomy.³⁸

CLINICAL FEATURES:

Clinical features of teeth with Dens invaginatus include incisal notching, peg-shaped development, pointed morphology, increased labio-lingual and mesio-distal width, and the occurrence of a distended palatal cingulum or cusp.³⁹ Clinical detection of the invagination entry can be difficult and be analogous to normal fissures. Methylene blue dye can be used to assist in the identification process.¹¹ Other diagnostic features are abscess and cyst development, dislocation of teeth, retention of neighboring teeth, internal resorption and cellulitis of face with undetected and untreated coronal invaginations.^{11,29,39}

The infolding permits ingress of irritants into vicinity that is separated from dental pulp by a thin sheet of enamel and dentine and has a tendency for the progression of dental caries. In a few cases incomplete enamel-coating and connections might be present between the infolding and the dental pulp.¹⁴ Hence, pulp necrosis frequently occurs in a

short period after tooth eruption, occasionally before closure of root ending.^{6,25}

RADIOGRAPHIC EXAMINATION:

Radiograph shows density of invaginations similar to that of enamel. The infolding of the enamel is generally more radio-opaque than the surrounding tooth structure and therefore can be recognized without problems.¹⁴ when the infolding involves the coronal or radicular part of the tooth, the shape of the pulp space may modify resulting in 'rounding' of the horns of dental pulp.²⁰ The invagination may differ in size and shape from a loop like, pear shaped radiolucent formation to a severe appearance similar to 'tooth inside a tooth'.^{1,6}

Type III (A) shows a deep fissuring of the tooth which egress on the one side of the root.¹⁷ The root canal adjoining to the infolding may be anomalous. Microbes entranced onward the invagination can develop a peri-invagination periodontitis.^{4,22} While connections between the invagination and the root canal can cause lose of vitality if the invagination is contaminated.^{24,40} On the contrary, kind III (B) of Dense invaginatus is more hard to detect because it overlay on the root canal structure and in many cases presents with a well developed periapical infection.^{5,32} The introduction of CBCT (cone-beam computed tomography) in clinical dentistry has aided not only in diagnosis but also provide support to the clinician in improved treatment planning of difficult cases requiring endodontic treatment.⁴⁶ Cone-beam computed tomography and surgical operating microscope not only help in the diagnosis, treatment-planning, endodontic treatment of a tooth with dens in dents and also improve the success rate.^{47,55} Early diagnosis is essential as, if left untreated; the channel will permit gathering of microorganisms and irritants.

MANAGEMENT OPTIONS:

PREVENTION:

Clinically and radiographically, tooth with Dens invaginatus is vital and there is no indication of disease, a preventive approach should be acquired.⁴⁸ Composite resin and fissure sealant are used to seal the pit of invagination followed by preventive recommendation and regular follow-up. If the teeth develop infection, treatment will be compulsory.⁴² The management modalities of alternatives will base on the following factors (Table 3).

The following treatment alternatives are offered for infected cases.⁴³

Table 3

Treatment modalities depend on following criteria^{41,42}

1	Function and aesthetics	Dens invaginatus commonly presents with anomalous crown shape which can have an effect on function, aesthetics or cause occlusal disturbances.
2	Configuration of root canal system	If the root canal morphology is complicated, access may not be easy and might result in entire crown destruction.
3	Stage of root development of tooth	Affected teeth with incomplete apices will need apexification before to completion of root canal therapy. Dens invaginatus has been reported in immature teeth.
4	Patient choice and co-operation	Due to the complexity of some treatments, co-operation is essential. Though, patients are often ready to keep the tooth, particularly an upper anterior tooth.

ROOT CANAL TREATMENT:

If the apex has not closed; then

- a). Apexification with the use of calcium hydroxide will be required.⁴⁹
- b). Mineral trioxide aggregate (MTA) can be utilized to make an apical barrier before the obturation of the canal. Obturation with warm gutta-percha techniques, (such as warm lateral condensation or thermoplastic methods) is usually the method of preference to ensure absolute filling of the canals.⁵⁰
- c). If the invagination has a separate apical foramen, and does not contact with the main pulp of the tooth, root canal treatment of the invagination can be done, thus maintaining the vitality of the pulp of the tooth.⁵¹
- d). Revascularization technique was used by Narayana Pet al⁵⁴, in 2012 for the management of a complex dens invaginatus with immature root apex. They used CBCT scans in diagnosis and treatment planning and surgical operating microscope in a step-by-step clinical procedure. Yang J,⁵⁹ in 2013 described a case report for type II immature dens invaginatus with pen-apical infection. He suggested that endodontic therapy with pulp revascularization should be considered prior to peri-apical surgery, with adequate infection control, pulp revascularization can be a successful

alternate technique.

SURGICAL ENDODONTICS:

If root canal therapy is not successful or if there is difficulty in gaining access to the canal, root end preparation and filling is the treatment of preference.⁵² When the type III invagination is present and root canal treatment is done, but gutta-percha extruded into periapical tissues during obturation of the root canal system.⁵³ In these cases, apical curettage and surgical endodontics can be done instantly if needed. Though, if there are no severe problems, it can be left and monitored regularly. Teeth with complex root canal morphology, in which adequate instrumentation is difficult, a combination of root canal treatment and root end preparation should be selected.^{49,53}

EXTRACTION:

In cases where adequate results cannot be attained with the above mentioned methods, extraction should be done.⁵²

MANAGEMENT OF TYPE I AND TYPE II DENS INVAGINATUS:

When this anomaly has been recognized base-line vitality assessment should be done to find existing pulpal condition. When pathological infection is

not present the commencement of suitable prophylactic procedures must start. (1). It comprised the preparation of the invagination entry and restores it with amalgam or modern fissure sealant.(2) Microscope and ultrasonic instruments are used to open up and gain access to the invagination entry. When the infolding is entirely uncovered, MTA may be utilized to fill the invagination and entrance opening will be preserved with composite. The tooth vitality should be regularly checked. (3). Root canal treatment should be started, If tooth lost vitality. An intra-canal medicament (such as calcium hydroxide) is used but in recent times triple antibiotic paste (ciprofloxacin, minocycline, metronidazole) has been applied. (4) If apex is opened, this problem is solved by forming apical plug either using calcium hydroxide or by MTA (mineral trioxide aggregate) (5). When endodontic treatment is not succeeds then combination of nonsurgical and surgical treatment could be carried out.^{56,58}

TYPE III:

Vital tooth related with pen-apical inflammation, this mal-development should be managed endodontically in the similar approach as a normal root canal to save the vitality of the pulp.^{57,59} In type III invagination, when pulp necrosis has occurred in a tooth is effectively handled by root canal treatment of the invagination alone, or with a collective endodontic and pen-apical surgery.⁵⁸ Ultrasonic can be applied for the entire elimination of invagination in a few cases to assist root canal treatment.⁵⁴ When the morphology of these teeth is compound, endodontic therapy is not achievable then extraction is generally suggested and prosthetic substitute is advised.⁵⁵ The option of planned re-implantation has also been discussed in very difficult class III dens invaginatus.^{58,59}

CONCLUSION:

Dens invaginatus is a developmental abnormality of teeth. Involved teeth demonstrate a deep invagination of enamel and dentine originating from the foramen caecum or the incline of the cusps, which can penetrate deep into the root. Maxillary lateral incisors are most affected teeth. It is crucial that dens invaginatus cases are identified early, before the development of periapical infection, so that a precautionary measure of sealing the invagination is taken and the tooth is then monitored. If the teeth develop infection and become non-vital,

the problems in root canal management should be kept in mind and explained to the patient mainly Type III cases, others options such as surgical intervention or extraction should be considered. The availability of 3- dimensional imaging system (CBCT) and use of a surgical microscope help in the removal of the dens part of a tooth without compromise the coronal tooth structure.

REFERENCES:

1. Zengin AZ, Sumer AP, CelenkP. Double dens invaginatus. *EurJ Dent* 2009; 3:67-70.
2. Beynon AD. Developing dens invaginatus (dens in dente). A quantitative microradiographic study and a reconsideration of the histogenesis of this condition. *Br Dent J* 1982;153, 255-60.
3. Ridell K, Mejåre I, Matsson L. Dens invaginatus: a retrospective study of prophylactic invagination treatment. *Int J Paediatr Dent* 2001; 11:92-7.
4. Gustafson G, Sunderberg S. Dens in dente. *Br Dent J* 1950; 88:111-22.
5. Atkinson SR. The permanent maxillary lateral incisor. *Am J Orthodont.* 1943; 29:685-98.
6. Hulsmann M. Dens invaginatus: etiology, classification, and prevalence diagnosis and treatment considerations. *Int J Endodont* 1997; 30: 79-90.
7. Tomes J. *A System of Dental Surgery* 3rd edn. London, UK: J and A Churchill, 1887: pp. 652-5.
8. Hallet GE. The incidence, nature and clinical significance of palatal invagination in maxillary incisors. *Proceedings of the Royal College of Medicine* 1953; 46: 491-9.
9. Silberman A, Cohenca N, Simon JH. Anatomical redesign for the treatment of dens invaginatus type III with open apices: a literature review and case presentation *JAm Dent Assoc*, 2006 ;137:180-5.
10. Hunter HA .Dilated composite odontome. *Oral Surg Oral Med Oral Pathol* 1951; 4:668-73.
11. Alani A, Bishop K. Dens invaginatus. Part 1: classification, prevalence, etiology. *Int Endod J* 2008; 41:1123-36.
12. Steffen H, Splieth C. Conventional treatment of dens invaginatus in maxillary lateral incisor with sinus tract: one year follow-up. *J Endod* 2005; 3 1:130-3.

13. Stamfelj I, Kansky AA, Gasperic D. Unusual variant of type 3 Dens invaginatus in a maxillary Canine: A rare case report. *J Endod* 2007; 33:64-8.
14. Kronfield R. Dens in dente. *J Dent Res* 1934;14: 49-66.
15. Rushton MA. A collection of dilated composite odontomes. *Br Dent J* 1937; 63:65-85.
16. Oehlers FAC. Dens invaginatus. Part I: variations of the invagination process and association with anterior crownforms. *Oral Surg Oral Med Oral Pathol* 1957;10 :1204-18.
17. Brust P. Uber die Entschung des, Dens undente, *Schweizer Monatsschrift fur Zahnheikunde* 1950;60: 534-42.
18. Sprawnson EC. Odontomes. *Brit Dent J* 1937;62:177-201.
19. Sapp JP, Eversole LR, Wysocki GP. *Contemporary Oral and Maxillo-facial Pathology*. 2nd ed. St Louis: Mosby. 2003:8-9.
20. Kettunen P, Laurikkala J, Itaranta P. Association of FGF- 3 and Fgf-10 with signaling networks regulating tooth morphogenesis. *Developmental Dynamics* 2000; 2 19:322-32.
21. Schultze C. Developmental abnormalities of the teeth and the jaws. In: Thomas's Oral Pathology. Gorlin O, Goldman H, eds. St Louis, USA: Mosby, 1970: pp. 96-183.
22. Hoviand E J, Block R M. Non recognition and subsequent endodontic treatment of dens invaginatus. *J Endod* 1977;3:360-2.
23. Cakici F, Celiekoglu M, Arsian H, Topcuoglu HS, Erdogan AS. Assessment of the prevalence and characteristics of dens invaginatus in a sample of Turkish Anatolian population. *Med Oral Pathol Oral Cir Bucal* 2010;15e:855-8.
24. Swanson WF, McCarthyFM. Bilateral dens in dente. *Journal of Dental research* 1947;26:167-71.
25. Ulmansky M, Hermel J. Double dens in dente in a single tooth. *Oral Surgery, Oral Medicine and Oral Pathology* 1964;17: 92-7.
26. Schuize C, Brand E. Uber den Dens Invaginatus (Dens in dente). *Zahnarztliche Welt, zahnarztliche Reform, ZWR* 1972; 81:569-73,613-20,653-60,699-703.
27. Oehlers FA. The radicular variety of dens invaginatus. *J Oral Surg Oral Med and Oral Pathol Oral Radiol Endod* 1958; 11:1251-60.
28. Damm N, Bouquet A. *Oral and Maxillofacial Pathology*. 3rd ed. Saunders 2009:90-3.
29. Ridell K, Meja're J, Matsson L. Dens invaginatus: a retrospective study of prophylactic invagination treatment. *Int J of Paediatric Dent* 2001; 11:92-7.
30. Bhaskar SN. *Orbans Oral Histology and Embryology*. 11th ed, Mosby Company, London, 1990: 44-9.
31. Omnell KA, Swanbeck G, Lindahl B. Dens invaginatus. II. A microradiographical, histological and micro X-ray diffraction study. Buchbinder SP, Vittinghoff E, HeagertyActa Odontologica Scandinavica 1960; 18, 303-30.
32. De Smit A, Jansen HW, Dermaut L. A histological investigation of invaginated human incisors. *Journal de Biologie Buccale* 1984;12: 20 1-9.
33. Piatelli A, Trisi P. Densinvaginatus: a histological study of undermineralized material. *Endodontics and Dental Traumatology* 1993; 9:191-5.
34. Morfis AS. Chemical analysis of a dens invaginatus by S E M microanalyses. *The Journal of Clinical Pediatric Dentistry*. 1993; 17:79-82.
35. Bloch-Zupan A, Cousandier L, Hemmerle J, Obry-Musset AM, Maniere MC. Electron microscopical assessments (FDI abstract FC-1 1# 123). *Int Dent J* 1995; 45:306.
36. Kramer IRH. The pathology of pulp death in non-carious maxillary incisors with minor palatal invaginations. *Proceedings of the Royal Society of Medicine* 1953; 46:503-6.
37. Seow WK. Diagnosis and management of unusual dental abscesses in children. *Australian Dental Journal* 2003 :48:156-68.
38. Patel S, Dawood DA, Ford TP. The potential applications of cone beam computed tomography in a management of endodontic problems. *Int Endod J* 2007;40:818-30.
39. Alani A. Densinvaginatus: a problem from the outside in. *Int Dent J* 2009;59:343-8.
40. Gotoh T, Kawahara K, Imai K, Kishi K.

- Fujiki Y. Clinical and radiographic study of dens invaginatus. *Oral Surg, Oral Med and Oral Pathol* 1979; 48: 88-9.
41. Bishop k, Alani A. Dens invaginatus. Part 2: Clinical, radiographic features and management options. *Int Endod J* 2008;41: 1137-54.
 42. Aguiar CM, Ferreira JP, Câmara AC, de Figueiredo JA. Type 2 dens invaginatus in a maxillary lateral incisor: a case report of a conventional endodontic treatment. *J Clin Pediatric Dent.* 2008;33:103-6.
 43. Bansal M, Singh NN, Singh AP. A rare presentation of dens in dente in the mandibular third molar with extra oral sinus. *J Oral Maxillofac Pathol* 2010;14:80-2.
 44. Kristofferson O, Nag OH, Fristad. Dens invaginatus and treatment options based on a classification system: report of a type II invagination. *Int Endod J* 2008;41 :702-9.
 45. Schmitz MS, Montagner F, Flores CB, Moran VHC. Management of dens invaginatus type land open apex. Report of three cases. *J Endod* 2010;36:1079-85.
 46. Roth JS. CBCT technology: endodontics and beyond, part I. *Dent Today* 2011; 30:146.148,150-1.
 47. Roth JS. CBCT technology: endodontics and beyond, part 2. *Dent Today* 2011;30:78.80-3.
 48. Trope M. Treatment of the immature tooth with a non—vital pulp and apical periodontitis. *Dent Clin North Am* 2010;54:313-24.
 49. Szajkis S, Kaufman AY. Root invagination: a conservative approach in endodontics. *J Endodont* 1993; 19: 576-8.
 50. Torabinejad M, Chivan N. Clinical application of Mineral trioxide aggregate. *J Endodont* 1999; 25: 197-205.
 51. Beltes P. Endodontic treatment in three cases of Dens invaginatus. *J Endodont* 1997; 23:399-440.
 52. Steffen H, Splieth C. Conventional treatment of Dens invaginatus in maxillary lateral incisor with a sinus tract: one-year follow-up. *J Endodont* 2005; 31: 130-3.
 53. da Silva Neto UX, Goto Hirani VH, Papalexiou V. Combined endodontic therapy and surgery in the treatment of Dens Invaginatus Type 3: case report. *J Can Dent Assoc* 2006; 71: 855-8.
 54. Narayana P, Hartwell GR, Wallace R, Nair UP. Endodontic Clinical Management of a Dens Invaginatus Case by Using a Unique Treatment Approach: A Case Report. *JOE* 2012;38: 1145-8.
 55. Kaneko T, Sakaue H, Okiji T, Suda H. Clinical management of dens invaginatus in a maxillary lateral incisor with the aid of cone-beam computed tomography: a case report. *Dent Traumatol* 2011 ;27:478-83.
 56. Schmitz MS, Montagner F, Flores CB, Morari VHC. Management of dens invaginatus type I and open apex. Report of three cases. *J Endod* 2010;36:1079-85.
 57. Jung M. Endodontic treatment of dens invaginatus type III with three root canals and open apical foramen. *Int Endod J* 2004;37:205-13.
 58. Kristofferson O, Nag OH, Fristad. Dens invaginatus and treatment options based on a classification system: report of a type II invagination. *In Endod J* 2008 ;41:702-9.
 59. Yang J, Zhao Y, Qin M, Ge L. Pulp Revascularization of Immature Dens Invaginatus with pen apical Periodontitis *JOE* 2013;39:288-92.