

## Transient Global Amnesia as a Presentation of Frontal Lobe Meningioma – A Case Report

Sidra Jazil Faruqi, Noor-us-Sabah, Maira Jamal, Muhammad Yahya

### ABSTRACT

Meningiomas are amongst the most common primary brain tumors, accounting for around one third of cases. They usually present with focal neurological deficits, signs of raised intracranial pressure or seizures. Transient global amnesia (TGA) is an uncommon disorder, usually linked with severe emotional or physical stress, migraine variant or vascular risk factors. It is believed to originate from hippocampal dysfunction. We present the case of a 65 year female, who visited our hospital with two episodes of transient amnesia. Both episodes lasted for 4-5 hours with no other focal neurological dysfunction noted. She fit the diagnostic criteria for TGA and seizures were ruled out by a normal sleep-deprived electroencephalogram (EEG). Magnetic Resonance Imaging (MRI) of Brain showed the presence of a right frontal meningioma. We conclude that she suffered from TGA secondary to right frontal meningioma, a rare association of which only a handful of cases have been reported worldwide.

**Keywords:** Brain neoplasms, Meningioma, Transient global amnesia.

### How to cite this Article:

Faruqi SJ, Sabah NU, Jamal M, Yahya M. Transient Global Amnesia as a Presentation of Frontal Lobe Meningioma – A Case Report. J Bahria Uni Med Dental Coll. 2020; 10(4): 322-324 DOI: <https://doi.org/10.51985/JBUMDC2020043>

### INTRODUCTION:

Transient global amnesia (TGA) was first described by two authors in the 1950s.<sup>1, 2</sup> It is a syndrome of retrograde amnesia which should completely resolve within 24 hours. Also, during this episode, the patient should have no other cognitive or neurological deficits. Once this episode has subsided, the patient usually has no recollection of the events. The most common causes of TGA are migraine variant, transient ischemic attack, emotional stress, severe pain, physical exertion or vasospasm.<sup>3,4</sup> Transient global amnesia occurring as a presenting feature of a brain tumour is extremely rare, with fewer than 20 cases reported worldwide till 2015.<sup>5</sup> The case of a 65 years old female, who presented with TGA to our hospital is presented here.

### CASE REPORT:

A 65 years female, right handed, with no known co-morbid conditions, presented to our Emergency Room with complains

of two episodes of transient amnesia. Each episode had lasted for 4-5 hours. The first episode occurred two days prior to admission and the second episode occurred on the day of admission.

Prior to the onset of both episodes, she was carrying out her routine activities at home. There was no history of any physical or emotional stress before these episodes. Her family members noted that she suddenly became very confused. She was unable to remember the day and the date. She also had no recollection of what task she was performing and what her plans for the day had been. Throughout the episode, she repeatedly kept asking her husband what was happening. The family noted no other neurological symptoms during these episodes. Both attacks resolved in 4-5 hours after which the patient had no recollection of the attack. There was no associated headache or loss of consciousness. She had no significant past history and was on no medications. She had no history of head injury, unconsciousness or seizures previously. She was a housewife with no family history of any neurological disorder.

On examination, she was vitally stable. Her Glasgow Coma Scale (GCS) was 15/15 with intact cranial nerve, motor, sensory and cerebellar examinations. On Frontal Lobe Assessment, her conceptualization, lexical fluency, orientation to time and place, speech and emotional state were normal with absent released reflexes. Calculation was impaired leading to a Mini Mental State Examination (MMSE) score was 27/30.

A diagnosis of TGA was considered according to diagnostic criteria. (Table 1)<sup>6</sup> Keeping in mind the association with vasospasm and differential diagnosis of Transient Ischemic

**Sidra Jazil Faruqi**  
Senior Registrar (Neurology), Department of Medicine,  
Hamdard University, Karachi  
E-mail: [sidra.faruqi@gmail.com](mailto:sidra.faruqi@gmail.com)

**Noor-us-Sabah**  
Interns, Department of Medicine,  
Hamdard University, Karachi

**Maira Jamal**  
Interns, Department of Medicine,  
Hamdard University, Karachi

**Muhammad Yahya**  
Professor, Department of Medicine,  
Hamdard University, Karachi

Received: 19-Jun-2020  
Accepted: 07-Sep-2020

Figure 1: Computed Tomography (CT) Scan Brain Plain (Axial view) showing a mixed density lesion in the right frontal lobe

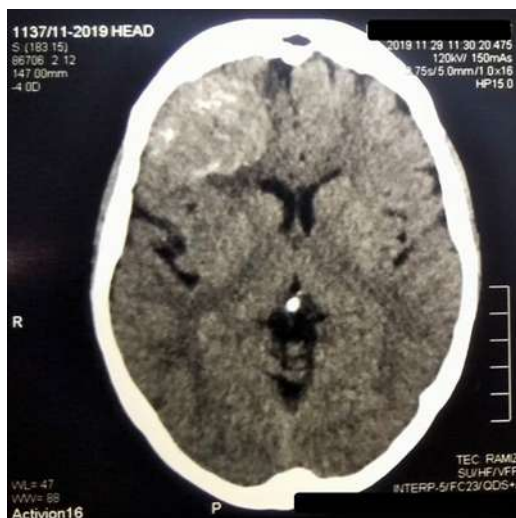
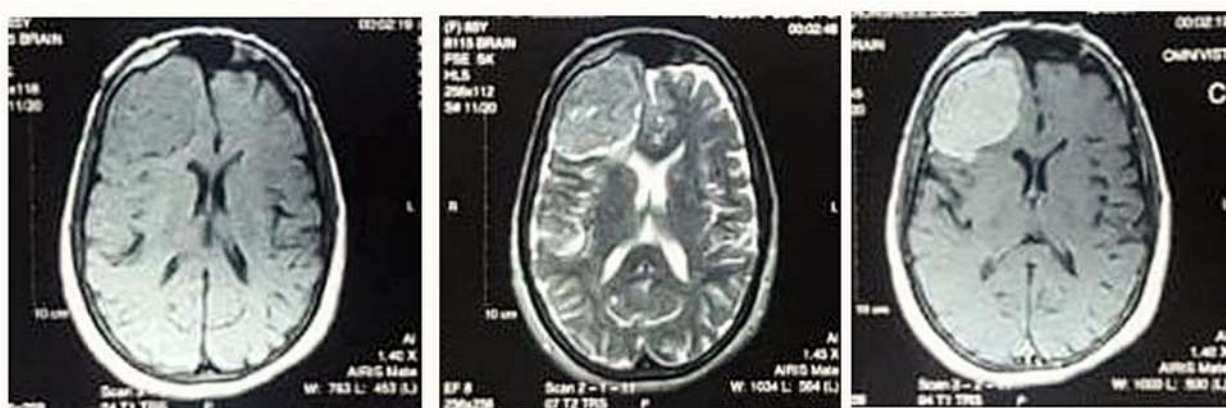


Table 1: Hodges and Warlow Criteria for diagnosis of transient global amnesia<sup>6</sup>

Hodges and Warlow Criteria for Transient Global Amnesia
Attacks must be witnessed
There must be anterograde amnesia during the attack
Cognitive impairment is limited to amnesia
No clouding of consciousness or loss of personal identity
No focal neurological signs/ symptoms
No epileptic features
Attacks must resolve within 24 hours
No recent head injury or active epilepsy

Figure 2: Magnetic Resonance Imaging (MRI) Brain (Axial View) showing a right frontal meningioma



Attack (TIA), neuro-imaging was carried out. Computed Tomography (CT) Scan Brain Plain showed a well circumscribed, mixed density lesion in the right frontal lobe suggestive of a meningioma (Fig 1). Magnetic Resonance Imaging (MRI) of the Brain with contrast showed an extra-axial area of abnormal signal intensity in the right frontal lobe that was isointense on T1 weighted image, mixed intensity on T2 weighted image with homogenous contrast enhancement (Fig 2). These findings represented a right frontal lobe meningioma.

All other investigations including a complete blood count, renal and liver function tests, metabolic panel, hepatitis B surface antigen, antibodies to hepatitis C virus, random and fasting blood sugars, glycated haemoglobin, fasting lipid profile, electrocardiography and echocardiogram were normal. An electroencephalogram that the patient had brought with her was normal. Considering the differential diagnosis of Transient Epileptic Amnesia (TEA), a sleep-deprived electroencephalogram was also performed which was normal for age and state.

A neurosurgery consultation was taken and surgery planned. Other than the above described episodes of amnesia, the patient experienced no further episodes. Following her surgery, she will be reassessed in the Neurology clinic.

**DISCUSSION:**

Meningiomas are amongst the most common of all central nervous system (CNS) tumours, accounting for approximately one third of all primary brain and spinal cord tumours.<sup>7</sup> A study conducted in Gwalior, India found that meningiomas comprised 26.17% of all brain tumours investigated during the study period.<sup>8</sup> These tumours arise from the arachnoid cap cells in the meninges and are easily diagnosed through neuro-imaging. Meningiomas commonly occur in the elderly (Age greater than 65 years) and in females.<sup>9</sup>

Meningiomas produce their typical symptoms through various mechanisms. They can cause symptoms by compressing the underlying brain parenchyma or cranial nerves.<sup>10</sup> Another mechanism of injury is direct invasion of the underlying structures, during which they may cause

vascular injuries as well.<sup>11</sup> The mechanism of injury as well as the site of the meningioma will determine the signs and symptoms that patients present with. The most common symptoms associated with meningiomas are headache due to increased intracranial pressure, focal neurological (including cranial nerve) deficits or generalized and partial seizures caused by focal mass effect. In frontal lobe or parasagittal meningiomas, personality changes, confusion and altered level of consciousness are often seen. These patients are often misdiagnosed as dementia or depression.<sup>12</sup> Our patient was diagnosed with a frontal lobe meningioma; however, she failed to show any of the signs or symptoms mentioned above.

Transient global amnesia is rarely associated with brain tumours. The pathophysiology still remains unclear with the consensus being that hippocampal dysfunction causes this particular phenomenon.<sup>13</sup> However, cases have been reported of TGA occurring with lesions distant to the hippocampus.<sup>14</sup>

Since meningiomas can cause seizures, both focal and generalized, and the closest differential to TGA is Transient Epileptic Amnesia (TEA), it is essential that seizures be ruled out in all patients presenting with episodic amnesia. In our patient, this is achieved by applying the diagnostic criteria for TGA (Table 1) and also performing a sleep deprived EEG. The EEG was normal for the patient's state and age. The duration of the patient's symptoms (4-5 hours) were greatly exceed the duration of an attack of transient epileptic amnesia (Usually less than 1 hour).<sup>15</sup>

On the basis of thorough investigations and MRI findings, it was concluded that this patient had transient global amnesia secondary to a frontal lobe meningioma. It is a rare association, but potentially treatable, and should be kept in mind when investigating patients with a similar presentation.

**CONCLUSION:**

Transient global amnesia may rarely occur as a consequence of space occupying lesions in the brain, even in lesions remote from the hippocampus. Imaging of the brain should be performed in all patients presenting with episodic amnesia and appropriate investigations should also be carried out to exclude seizures.

**Author Contribution:**  
 Sidra Jazil Faruqi: Data collection and manuscript writing  
 Noor-us-Sabah: Data collection and manuscript writing  
 Maira Jamal: Data collection and manuscript writing  
 Muhammad Yahya: Data collection and manuscript writing

**REFERENCES:**

1. Bender MB. Syndrome of isolated episode of confusion with amnesia. *J Hillside Hosp.* 1956;5: 212–215.
2. Courjon J, Guyotat J. Amnesic strokes. *J Med Lyon.* 1956; 37(882):697-701.
3. Portaro S, Naro A, Cimino V, et al. Risk factors of transient global amnesia: Three case reports. *Medicine (Baltimore).* 2018;97(41):e12723.
4. Saura D, Peñafiel P, Morales A, Albert L, Martínez F, de la Morena G. Transient global amnesia after dobutamine--atropine stress echocardiography. *Eur J Echocardiogr.* 2008;9(4):567-8.
5. Milburn-McNulty P, Larner AJ. Transient global amnesia and brain tumour: chance concurrence or aetiological association? Case report and systematic literature review. *Case Rep Neurol.* 2015;7(1):18-25.
6. Hodges JR, Warlow CP. Syndromes of transient amnesia: towards a classification. A study of 153 cases. *J Neurol Neurosurg Psychiatry.* 1990;53(10):834-843.
7. Ostrom QT et al. CBTRUS statistical report: primary brain and central nervous system tumors diagnosed in the United States in 2008-2012. *Neuro-oncology.* 2015 Oct 1;17(suppl\_4):iv1-62.
8. Shukla, A., Gupta, A. K., Sharma, A., & Iyengar, S. N. Epidemiological study of intracranial meningiomas in a tertiary care hospital. *Romanian Neurosurgery,* 2019;33(1): 80-86.
9. Holleczeck B, Zampella D, Urbschat S, et al. Incidence, mortality and outcome of meningiomas: A population-based study from Germany. *Cancer Epidemiol.* 2019;62:101562.
10. Pieper DR, Al-Mefty O, Hanada Y, Buechner D. Hyperostosis associated with meningioma of the cranial base: secondary changes or tumor invasion. *Neurosurgery.* 1999; 44(4):742-6; discussion 746-7.
11. Hallinan JT, Hegde AN, Lim WE. Dilemmas and diagnostic difficulties in meningioma. *Clin Radiol.* 2013;68(8):837-44
12. Buerki RA, Horbinski CM, Kruser T, Horowitz PM, James CD, Lukas RV. An overview of meningiomas. *Future Oncol.* 2018;14(21):2161-2177.
13. Bartsch T, Alfke K, Deuschl G, Jansen O (2007) Evolution of hippocampal CA-1 diffusion lesions in transient global amnesia. *Ann Neurol.* 62:475Y480.
14. Dinca EB, Carron R, Gay E. Transient global amnesia as a revealing sign of giant transtentorial meningioma: case report and review of the literature. *J Nerv Ment Dis.* 2011;199(6):416-418.
15. Ramanan VK, Morris KA, Graff-Radford J, Jones DT, Burkholder DB, Britton JW, Josephs KA, Boeve BF, Savica R. Transient epileptic amnesia: a treatable cause of spells associated with persistent cognitive symptoms. *Frontiers in neurology.* 2019;10:939.

