

Role of Magnetic Resonance Spectroscopy in Differentiating Neoplastic From Non-Neoplastic Ring Enhancing Brain Lesions Taking Surgical Findings as Gold Standard

Ameet Jesrani, Marya Hameed, Seema Nayab, Asma Javed, Sehrish Sethar

ABSTRACT

Objective: To evaluate the diagnostic accuracy of Magnetic Resonance spectroscopy (MRS) in distinguishing neoplastic from non-neoplastic ring enhancing brain lesions taking histopathological findings as gold standard.

Study Design and Setting: The cross sectional study was conducted at Radiology department of Jinnah Postgraduate Medical Centre.

Methodology: Total 102 patients with ring enhancing lesions detected on MRI brain contrast studies were selected for this study. Cases were referred from Outpatient Department of Neurology Clinics who were suspected of having space occupying lesions in brain. Full history, clinical examination and laboratory investigations (Complete Blood Count and ESR) were carried out. The patients having claustrophobia, metallic implants, cardiac pacemaker and having metallic foreign body in situ were excluded from the study. Informed consent was taken from the research and MRS was performed. On MRS, lesion was categorized and final diagnosis was taken based on histopathology results. All the information was recorded into predesigned proforma. Patients Data was scrutinized by using Statistical Package for Social Sciences (SPSS 21.0). Mean + SD was calculated for age, gender, duration of symptoms and size of the lesion.

Results: The average age of the patients was 35.45±10.36 years. Sensitivity, specificity, PPV, NPV and accuracy of MRS was 87.5%, 93.3%, 95.5%, 89.7% and 92.1% respectively.

Conclusion: Magnetic resonance spectroscopy can be effective in discerning neoplastic from non-neoplastic ring enhancing cerebral lesions, thus avoiding an invasive procedure like brain biopsy.

Key Words: Brain lesions, Magnetic resonance spectroscopy, Neoplastic, Non-neoplastic, Ring Enhancing.

How to cite this Article:

Jesrani A, Hameed M, Nayab S, Javed A, Sethar S. Role of Magnetic Resonance Spectroscopy in Differentiating Neoplastic From Non-Neoplastic Ring Enhancing Brain Lesions Taking Surgical Findings as Gold Standard. J Bahria Uni Med Dental Coll. 2020;10(3): 176-80 DOI: <https://doi.org/10.51985/JBUMDC2019078>

INTRODUCTION:

Magnetic resonance spectroscopy (MRS) is an application of MRI that early detects the abnormal chemical metabolites of brain tissue.¹ First clinically used in 1980s, it has proved to be useful in providing molecular information about the tumor and non tumoral cells of the brain tissue.² After true

detection of the benign or malignant lesions on MRS, many patients are saved from undergoing unnecessary surgeries.

Ring-enhancing lesions are frequently encountered neurological lesions and provide a challenge to neuroimaging. Typical location of ring-enhancing lesions is at the junction of the gray and white matter, however they can also be seen in the sub-cortical area, deep in the brain parenchyma or may even be superficial.³ Cerebral ring-enhancing lesions may present as non-tumorous conditions like abscesses, tuberculomas, multiple sclerosis, resolving hematoma (age 10-21days) or even post radiation necrosis. These conditions can easily mimic primary brain tumors or metastasis.⁴

Some of non neoplastic lesions show changes in MRS like raised Cho/Cr ratio with a suppressed NAA peak in Alexander's leukodystrophy⁵ while lower concentration of all metabolites, except Cr, in adult onset autosomal dominant leukodystrophy. Gupta R et al⁶ described the presence of lipid/lactate peak in both pyogenic and tuberculous abscesses, however, more frequently in tuberculous lesions. Distinguishing neoplastic from non-neoplastic ring-enhancing and tumor mimicking lesions is extremely important which if misdiagnosed may not only lead to unwarranted neuro-

Ameet Jesrani

Assistant Professor, Department of Radiology,
Sindh Institute of Urology and Transplantation, Karachi
Email: ameet.jesrani@yahoo.com

Marya Hameed

Consultant Radiologist, Department of Radiology,
Jinnah Postgraduate Medical Center, Karachi

Seema Nayab

Assistant Professor, Department of Radiology,
Liaquat University of Medical and Health Sciences, Jamshoro

Asma Javed

Resident, Department of Radiology,
Sindh Institute of Urology and Transplantation, Karachi

Sehrish Sethar

Resident, Department of Radiology,
Sindh Institute of Urology and Transplantation, Karachi

Received: 15-July-2019

Accepted: 17-June-2020

surgery, noxious chemotherapy or harmful irradiations but also prove to be fatal in many cases. Conventional MRI shows only 61.4%⁷ sensitivity in separating benign from malignant lesions even with the use of exceptional soft tissue contrast.

Magnetic resonance spectroscopy (MRS) significantly increases the diagnostic accuracy when used as an adjunct with conventional MRI. MRS determines the concentration of specific metabolites of different neurological pathologies in a pre-selected volume of brain tissue.^{8,9} Therefore, in newer imaging, MRS is emerging as a capable diagnostic tool in identifying several neurological and neurosurgical disorders with sensitivity and specificity of 97.6%¹ and 71.42%¹⁰ respectively.

The rationale of this study was the intention to determine the diagnostic accuracy of magnetic resonance spectroscopy which is cost effective, noninvasive and does not involve ionizing radiations in detecting neoplastic from non-neoplastic ring enhancing brain lesions and to standardize its use to determine the best management.

METHODOLOGY:

This cross-sectional study was executed from 9th January 2019 till 10th July 2019 in Radiology department of Jinnah Postgraduate Medical Centre after approval from ethical committee. Total 102 patients with ring enhancing lesions detected on MRI brain contrast studies were selected with patient's age ranging from 16 to 70 years. The mean age was 35.45±10.36 years of both genders. Cases were referred from Outpatient Department of Neurology Clinics who were suspected of having space occupying lesions in brain. Full history, clinical examination and laboratory investigations (Complete Blood Count and ESR) were carried out.

The patients having claustrophobia, metallic implants, cardiac pacemaker and having metallic foreign body in situ were excluded from the study. Informed consent was taken from the research and ethical committee of the institution. Sample size was calculated considering both the sensitivity and specificity of magnetic resonance spectroscopy to differentiate neoplastic from non neoplastic ring enhancing brain lesions. Nonprobability consecutive sampling technique was applied to collect the samples. Patient's history regarding duration of symptoms and demographic details like patient's age and gender was noted. Patients were subjected to Toshiba 1.5 Tesla MR Scanner. Various sequences were carried out with and without contrast like T1, T2 and Fluid Attenuated Inversion Recovery using a head coil. Then MRS was performed via single voxel technique using main metabolites like NAA which appears at 2.01ppm, Cho at 3.22ppm, Cr at 3.02, lipid at 0.8 to 1.3ppm and lactate at 1.32 to 1.33ppm.

Lesions with increased Choline and reduced NAA levels along with increased Cho/Cr ratio of more than 1.5 were labelled as neoplastic. While non-neoplastic lesions have reduced Cho, Cr and NAA levels.² Final results were

evaluated based on the histopathology results.

Statistical analysis was performed by using Statistical Package for Social Sciences (SPSS 21.0) as to obtain sensitivity and specificity of MRS in the differentiation of neoplastic from non-neoplastic ring enhancing brain lesions while taking histopathology as gold standard. Frequency and percentage was calculated for qualitative variables, i.e, presenting complains, detailed history of presenting complains; MRS findings and histopathological findings.

Mean ± SD was computed for quantitative variable, i.e. Age of the pateint. Taken histopathological results as gold standard, all statistical parameters, (sensitivity, specificity, positive predictive value, negative predictive value) were estimated to obtain diagnostic accuracy of MRS.

Patients Data was scrutinized by using Statistical Package for Social Sciences (SPSS 21.0). Mean + SD was calculated for age, duration of symptoms and size of the lesion. Frequency and percentage was computed for qualitative variables like gender, benign and malignant ring enhancing cerebral lesions using MRS and histopathology. With histopathology findings as gold standard; the sensitivity, specificity, positive predictive value, negative predictive value and diagnostic accuracy of magnetic resonance spectroscopy findings were calculated using 2 x 2 tables. Stratification was done on age, gender, duration of symptoms and size of the lesion.

RESULTS:

A total of 102 patients with ring enhancing lesions detected on MRI brain contrast studies were included in this study. There were 60.78% (62/51) male and 39.22% (40/51) female. Diagnostic precision of magnetic resonance spectroscopy in separating neoplastic from non-neoplastic ring enhancing brain lesions is presented in table 1. Sensitivity, specificity, PPV, NPV and accuracy of MRS was 87.5%, 93.3%, 95.5%, 89.7% and 92.1% respectively.

DISCUSSION:

Magnetic resonance spectroscopy provides useful chemical

Table 1: Diagnostic accuracy of MRS in segregating neoplastic from non-neoplastic ring enhancing brain lesions taking histopathology as gold standard

Magnetic Resonance spectroscopy Findings	Histopathology		Total
	Positive	Negative	
Neoplastic	42 (TP)	2 (FP)	44(43.1%)
Non neoplastic	6 (FN)	52 (TN)	58(56.9%)
Total	48(47.1%)	54(52.9%)	102
Sensitivity	87.5%		
Specificity	93.3%		
PPV	95.5%		
NPV	89.7%		
Accuracy	92.1%		

information which cannot be really provided by conventional CT scan and MRI.¹¹ MRS was first used in 1980s.¹² Since then, it is targeting primarily patients with brain cancer.¹¹⁻¹³ When studied about human brain proton MRS, it was known that brain cancer cells exhibit dissimilar spectra from normal brain tissue.¹⁴

Lesions showing decreased levels of N-acetyl aspartate (NAA) and frequently increased levels of Choline (Cho), leading to increased Cho/NAA ratios were recognized as neoplastic lesions. So, on the basis of ratios of Cho/NAA and Cho/Cr, patients with heterogeneous brain lesions evaluated for suspected neoplasm show a higher rate of success of 94% accuracy in correctly classifying lesions as neoplastic and non-neoplastic lesions. Choline is contained in tumor cell membranes and gives elevated signals on MRS when there is tumoral cell proliferation and products degradation. It is presumed that tumoral levels of NAA originate from remaining brain tissue within a penetrating tumor. Few studies^{15, 16} showed even GBM could be differentiated from metastasis from MRS absolute lipid and macromolecular signals. LM13 class was found to be 85% accurate in tumor detection. Another metabolite MM12-fucose peak is yet to prove a role in molecular biology of brain metastasis^{15,16} which was lower than in non-neoplastic lesions.

In present study, the average age of the patients was 35.45±10.36 years. There were 60.78% (62/51) male and 39.22% (40/51) female. In Rehman et al study¹ 40% were females and 60% were males with mean age of 37 ±13.24 years. In Surur et al study¹⁷ women (57.9%) and 24 men (42.1%) and aged between 12 and 81 years (35 years average).

The results of this study depicted the sensitivity (87.5%), specificity (93.3%) and accuracy (92.1%) which are comparable to the previous studies reported sensitivity of 97.6%), specificity (71.42%) and accuracy (94%).¹ Other study reported the sensitivity of 87%, specificity of 85% and diagnostic accuracy of 88.2%³ for spectroscopy.^{18,19} In this study, PPV and NPV were 95.45% and 83.3%; while

one study has found 93% PPV and 70% NPV.² One study showed sensitivity of 91.7% and specificity of 94.3%²⁰ which is comparable than our results.

Figure 1 (a and b) shows ring enhancing lesion in right parietal lobe of brain and its MRS shows reduced peak of N-acetyl aspartate (NAA) and significantly raised peak of Choline and high choline to creatine ratio, findings on MRS are suggestive of neoplastic lesion.

Figure 2 (a and b) shows ring enhancing lesion in left parietoccipital lobes of brain and its MRS shows elevated lipid/lactate peak, findings on MRS are suggestive of brain abscess.

MR spectroscopy may also guide us about the organisms accountable for the abscess. Anaerobic bacteria are shown to elevate the levels of acetate and succinate peaks. Whereas, absence of acetate and succinate signals are more likely associated with obligate aerobes or facultative anaerobes.¹⁸ MRS can distinguish high-grade gliomas from metastases, especially with effective peritumoral measurements. This also supports the theory that MRS can detect infiltration of tumor cells in the peritumoral edema.¹⁹ Study conducted by Alam MS et al²⁰ revalidates this technique as highly sensitive in differentiating between neoplastic and non-neoplastic brain lesions although it was not very specific. Cho level was significantly increased in brain tumours due to an increase in mitotic activity which is not present in non-neoplastic lesions. This study showed median Cho levels of 2.15 in neoplastic lesions compared to non-neoplastic lesions of 1.03 which makes it single best marker to differentiate between the two types of brain lesions^[21] while our study show median choline level of 1.75 in neoplastic lesions which is again mentioning almost same values and characteristics. Our study has two false positive and six false negative cases while study conducted by Alam MS et al. has six false positive and six false negative²¹ which signifies more reliable results in our study. In one study more reliable results were noted which showed three false negative and three false positive cases²², however this study

Figure 1(a): Ring enhancing lesion in right parietal lobe crossing the midline

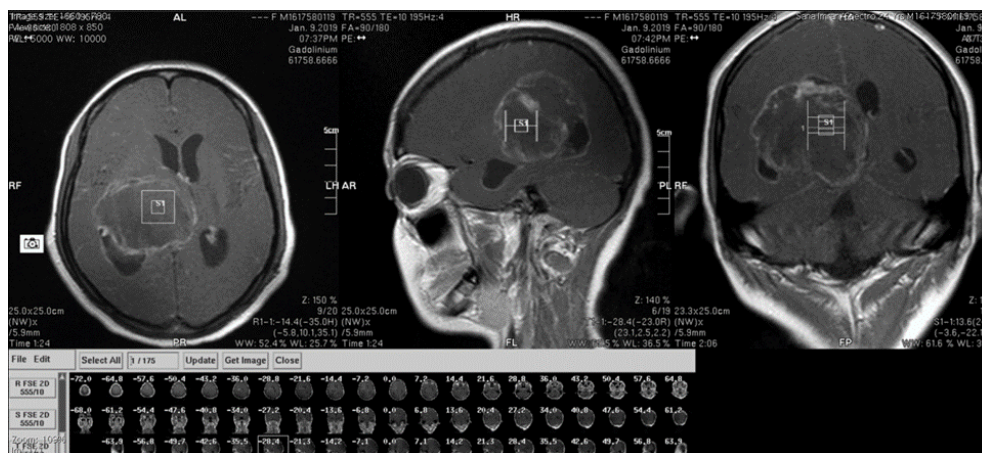


Figure 1(b): MRS of lesion in right parietal lobe shows elevated choline peak and reduced NAA peak

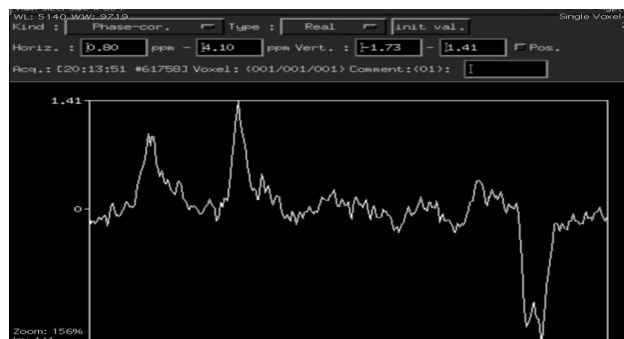


Figure 2(a): Ring enhancing lesion in left parietoccipital lobes with perilesional edema

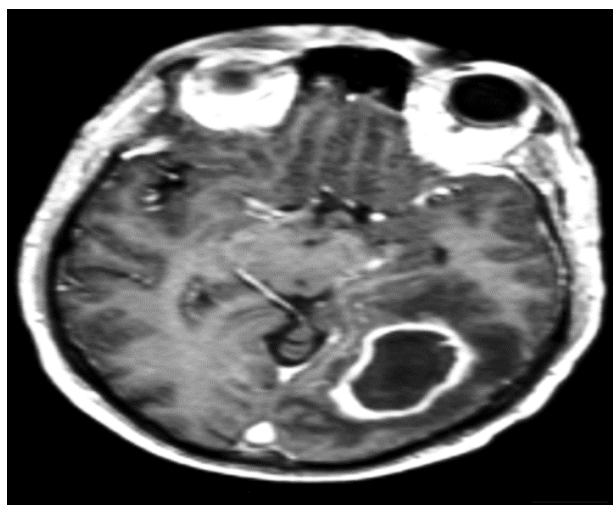
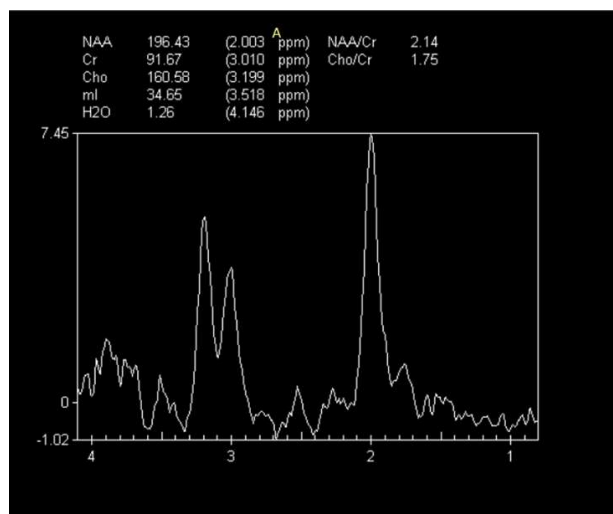


Figure 2(b): MRS of lesion in left parietoccipital lobes shows elevated lipid/lactate peak



showed diagnostic accuracy of 83% while our study revealed the diagnostic accuracy of 92.1% which signifies present study more. MRS is helpful for categorizing and classifying brain tumors.²³ Gliomas of each grade exhibit some specific

MRS features which again improve the diagnostic value of conventional magnetic resonance imaging.²⁴

Few limitations apply to this study. First, this study was conducted in one center of a private hospital and, hence, a certain demographics variables were observed. Second, sample size was small hence more sample size is required to generalize the specific findings and results.

CONCLUSION:

By using non invasive technique of MRI like MRS, invasive procedures such as brain biopsy can be avoided in differentiating neoplastic from non neoplastic ring enhancing brain lesions thus reducing the morbidity and mortality.

Author Contribution:

Ameet Jesrani: Written, revised and finalized manuscript
 Marya Hameed: Provided data
 Seema Nayab: Revised Manuscript
 Asma Javed: Written Manuscript
 Sehrish Sethar: Written Manuscript

REFERENCES:

1. Rehman L, Rehman UL, Azmat SK, Hashim AS. Magnetic Resonance Spectroscopy: Novel Non-invasive Technique for Diagnosing Brain Tumors. *J Coll Physicians Surg Pak.* 2015;25(12):863–66.
2. Alam MS, Sajjad Z, Hafeez S, Akhter W. Magnetic resonance spectroscopy in focal brain lesions. *J Pak Med Assoc* 2011;61:540-3.
3. Rezvanizadeh A, Firouznia K, Salehi-Sadaghiani M, Mohseni M, Gharaei D, Ghanaati H, Rad SH, Masoudnia M. The effects of voxel localization and time of echo on the diagnostic accuracy of cystic brain tumors in 3 tesla magnetic resonance spectroscopy. *Iran J. Radiol.* 2012;9:195–201
4. Chiang IC, Hsieh TJ, Chiu ML, Liu GC, Kuo YT, Lin WC. Distinction between pyogenic brain abscess and necrotic brain tumour using 3-tesla MR spectroscopy, diffusion and perfusion imaging. *Br J Radiol.* 2009;82(982):813-20
5. MRS findings in a patient with juvenile-onset Alexander's leukodystrophy. Nelson A, Kelley R, Nguyen J, Palacios E, Neitzschman HR. *J La State Med Soc.* 2013;165:14–17.
6. Gupta R, Vastal D, Husain N, Chawla S, Prasad K, Roy R, et al. Differentiation of tuberculous from pyogenic brain abscesses with in vivo proton MR spectroscopy and magnetization transfer MR imaging. *AJNR Am J Neuroradiol* 2001; 22: 1503-9.
7. Möller-Hartmann W, Herminghaus S, Krings T, Marquardt G, Lanfermann H, Pilatus U et.al. Clinical application of proton magnetic resonance spectroscopy in the diagnosis of intracranial mass lesions. *Neuroradiology.* 2002 ;44(5):371-81.
8. Ostrom QT, Gittleman H, Fulop J, Liu M, Blanda R, Kromer C et al CBTRUS Statistical Report: Primary Brain and Central Nervous System Tumors Diagnosed in the United States in 2008-2012. *Neuro Oncol* 2015;17 Suppl 4:iv1.
9. Rakesh KGupta, Jobanputra, Kamlesh J, Yadav, Abhishek. MR Spectroscopy in Brain Infections. *Neuroimaging Clinics of North America* August 2013; 23(3):475-498.

10. Débora Bertholdo, Arvemas Watcharakorn, Mauricio Castillo. Brain Proton Magnetic Resonance Spectroscopy. *Neuroimaging Clinics of North America*. 2013;23(3):359-80.
11. Chris D, Andrew WB, Susan MN, Michael WM, Nicholas MB, Mark RD, et al. Pre-operative proton MR spectroscopic imaging of brain tumors: correlation with histopathologic analysis of resection specimens. *AJNR Am J Neuroradiol* 2001;22:604-12.
12. Usenius T, Usenius JP, Tenhunen M. Radiation-induced changes in human brain metabolites as studied by ¹H nuclear magnetic resonance spectroscopy in vivo. *Int J Rad Oncol Biol Phys* 1995;33:719-24.
13. Majós C, Aguilera C, Alonso J, Julià M, Castañer S, Sánchez JJ, et al. Proton MR spectroscopy improves discrimination between tumor and pseudotumoral lesion in solid brain masses. *AJNR Am J Neuroradiol* 2009; 30:544-51.
14. Tate AR, Underwood J, Acosta D. Development of a decision support system for diagnosis and grading of brain tumors using in vivo magnetic resonance single voxel spectra. *NMR Biomed*. 2006;19:411-34.
15. Crisi G, Orsingher L, Filice S. Lipid and macromolecules quantitation in differentiating glioblastoma from solitary metastasis: a short-echo time single-voxel magnetic resonance spectroscopy study at 3 T. *J Comput Assist Tomogr*. 2013; 37:265-71.
16. Negendank WG, Sauter R, Brown TR. Proton magnetic resonance spectroscopy in patients with glial tumors: a multicenter study. *J Neurosurg*. 1996; 84:449-58.
17. Surur A, Cabral JF, Marangoni A, Marchegiani S, Palacios C, Herrera E. Contributions of magnetic resonance spectroscopy in brain lesions. *RAR*. 2010;74:239-249.
18. Hölzer T, Herholz K, Jeske J, Heiss WD. FDG-PET as a prognostic indicator in radiochemotherapy of glioblastoma. *J Comput Assist Tomogr* 1993;17:681-7.
19. Server A, Josefsen R, Kulle B. Proton magnetic resonance spectroscopy in the distinction of high-grade cerebral gliomas from single metastatic brain tumors. *Acta Radiol*. 2010;51:316-25.
20. Naz F, Mirza WA, Hashmani N. Combining Magnetic Resonance Spectroscopy and Magnetic Resonance Imaging in Diagnosing Focal Brain Lesions in Children. *Cureus* 2017;9(8):e1541.
21. Alam MS et al. Magnetic Resonance Spectroscopy of enhancing brain lesions: Analysis of 78 histopathology proven cases. *Journal of Pakistan Medical Association*.2014;64(10): 1141-5.
22. Alam MS., et al. "Magnetic resonance spectroscopy in focal brain lesions". *Journal of Pakistan Medical Association* 61.6 (2011): 540-543.
23. Ha DH, Choi S, Oh JY, Yoon SK, Kang MJ, Kim KU. Application of (³¹P) MR spectroscopy to the brain tumors. *Korean J Radiol*. 2013;14:477-86.
24. Bulik M, Jancalek R, Vanicek J, Skoch A, Mechl M. Potential of MR spectroscopy for assessment of glioma grading. *Clin Neurol Neurosurg* 2013;115:146-53.

