

## Evaluation of Mandibular Ridge Lingual Concavity Using Cone Beam Computed Tomography

Moiza Ijaz, Saira Ibrahim, Ayesha Aslam, Abdul Rehman, Sameena Younis, Ammara Shrafat

### ABSTRACT

**Objective:** To evaluate the type and depth of lingual concavity in posterior mandible using pre-treatment CBCT (Cone Beam Computed Tomography) images for dental implants.

**Study Design and Setting:** A cross-sectional study was designed and conducted on pre-treatment CBCT scans of 75 patients at Armed Forces Institute of Dentistry, Rawalpindi, Pakistan from February 2018 to November 2018.

**Methodology:** Pre-treatment CBCT scans of 75 patients were selected and following parameters were measured: type of ridge (undercut, parallel, convex), ridge width, ridge height, depth of lingual concavity, concavity angle, and location of the undercut. Data was analyzed using SPSS version .24. Post-stratification Mann-Whitney U test was used for effect modifiers, while Kruskal-Wallis test was used to compare study parameters between groups. P value <0.05 was taken as significant.

**Results:** A mean concavity depth of  $1.17 \pm 1.40$  mm was observed while majority (46.7%) of the CBCT images presented with undercut type ridge. No significant difference was observed between males and females for any study parameter.

**Conclusion:** Undercut ridges were frequently observed, posing a threat of lingual perforation during implant placement. Pre-operative assessment of implant site using CBCT can serve as a reliable method to avoid such complications.

**Keywords:** Alveolar Ridge, Cone beam computed tomography, Dental Implant, Mandible.

### INTRODUCTION:

In contemporary dentistry, the primary goal is to restore the patient's function, esthetics, comfort, speech and optimum oral health.<sup>1</sup> In consideration of these goals, dental implants have become a significant factor and have proved to be the closest equivalent in replacement of natural teeth. Success and outweighing of dental implants to other viable treatment options is mainly due to their superior biocompatibility, stability, maintenance of bone, strength and survival.<sup>2</sup>

However, in spite of their higher survival rates, certain

factors such as failure in diagnosis and proper treatment planning may lead to failure of implants. These factors therefore must be taken into consideration prior to placement of implants. Surgical complications during implant placement is one of the factor that cannot be underestimated.<sup>3</sup> McDermott et.al. in a retrospective study on 677 patients reported an overall higher frequency of surgical complications associated with implant placement.<sup>4</sup> Implant angulation generally follows the long axis of occlusal forces in the posterior region of the dental arch.<sup>5</sup> This is because bone can resist compression forces better than tensile or shear stresses.<sup>6</sup> An axially loaded implant can direct more compressive than tensile or shear forces on bone. In addition, better stress/strain distribution is possible when implants are placed along the axis of loading with multiple areas of cortical contact.<sup>7</sup>

One of the main surgical accident that can occur is the perforation of osseous boundaries during the placement procedure especially in the posterior lingual concavity.<sup>8</sup> This can lead to numerous complications including infection, inflammation, damage to other vital structures and eventually implant loss.<sup>9</sup> The cause of perforation in posterior mandible is the presence of lingual concavity which is due to the presence of submandibular and sublingual salivary gland.<sup>10</sup>

Mandible morphology and contour has previously been described by Zarb but buccolingual dimensions and concavities have not been covered in the classification.<sup>11</sup> Quiryen et.al. have conducted a cross-sectional study on inter-foraminal morphology and presence of lingual concavity.<sup>12</sup> Chan et.al. measured the depth of this concavity in the mandibular molar area and classified the ridges

#### Moiza Ijaz

Postgraduate Resident, Department of Prosthodontics, Armed Forces Institute of Dentistry, Rawalpindi

#### Saira Ibrahim

Postgraduate Resident, Department of Prosthodontics, Armed Forces Institute of Dentistry, Rawalpindi

#### Ayesha Aslam

Senior Lecturer, Department of Prosthodontics, Army Medical College / Armed Forces Institute of Dentistry, National University of Medical Sciences (NUMS), Rawalpindi  
Email: dr.ayesha.aslam@hotmail.com

#### Abdul Rehman

Assistant Professor, Department of Prosthodontics, Army Medical College/ Armed Forces Institute of Dentistry, National University of Medical Sciences (NUMS), Rawalpindi

#### Sameena Younis

Postgraduate Resident, Department of Prosthodontics, Armed Forces Institute of Dentistry, Rawalpindi

#### Ammara Shrafat

Postgraduate Resident, Department of Prosthodontics, Armed Forces Institute of Dentistry, Rawalpindi

Received: 12-06-2019  
Accepted: 25-11-2019

according to their morphology as being undercut, parallel or convex.<sup>8</sup> Familiarity with various vital structures in the region of prospective implant placement, along with thorough treatment planning, is the guaranteed way to avoid surgical complications.<sup>13,14</sup> Lekholm&Zarb described five stages of jaw bone resorption, describing them from least to most and then used this classification in treatment planning of implants.<sup>15</sup> Their area of interest was volume alterations of the residual ridge after extraction of tooth. Later, the ridge morphology in the inter-foraminal region was discussed thoroughly and the incidence of lingual undercut was labelled as “potential risk” of intra-operative complications.<sup>12,16</sup> However, for the posterior mandibular, data about lingual concavity is apparently infrequent. Such concavity can be detected by many methods each having own limitations. Nowadays, best available modality is cone-beam computed tomography (CBCT) as it has comparatively less radiation exposure and allows three-dimensional visualization.<sup>8,17</sup> An accurate radiograph serves as a useful guide for surgeon, as it helps determine fixture size and informs about ridge concavities.<sup>18</sup>

The aim of this study was to evaluate the type and depth of lingual concavity in posterior mandible in the local population using pre-treatment CBCT images for dental implants.

#### METHODOLOGY:

A cross-sectional study was designed and conducted at Armed Forces Institute of Dentistry, Rawalpindi, Pakistan from February 2018 to November 2018. Prior approval from Institutional Ethics Committee was taken. Based on previously published data,<sup>19</sup> keeping confidence level ( $1-\alpha$ ) at 95%, absolute precision (d) at 0.2, population mean ( $\mu$ ) at 2.4, population standard deviation ( $\sigma$ ) at 1.1, a total sample size of 75 was calculated. CBCT scans of patients taken using a NewTomVGI CBCT machine (QR s.r.l, Italy) for the purpose of pre-implant planning were selected. Informed consent was taken from the selected subjects to use their data anonymously for research. Scans of both male and female patients, aged 20-60 years, taken three months after extraction of mandibular first molar were included. The area of interest was edentulous ridge in the region of mandibular first molar, where the first molar itself should be absent but not the second premolar, with adequate vertical bone height in the area (12 mm between ridge crest and upper border of IAN canal) and bone width > 4 mm. Patients with bony pathologies were excluded as were CBCT images with artifacts that made identification of reference points difficult.

Figure 1 illustrates different measurements taken of mandibular cross-sectional morphology. On a given cross section under study, the region above the horizontal line X (2 mm above upper border of IAN canal) was evaluated, as the recommended implant position is 1.5 mm above IAN. Buccolingual width of the ridge 2 mm superior to IAN (Wa) and 2 mm inferior to the level of alveolar crest (Wb) was

measured. Most prominent point on lingual aspect of the ridge was labelled as point A. Point B was intersection of line X and lingual plate. Distance between residual ridge crest and line X (Va) was measured. Three types of cross-sectional mandibular ridge morphology were determined. Undercut (U) ridge type indicated a ridge with a narrow base and wider crest buccolingually with a prominent point A on lingual aspect, when studied in cross section. Parallel (P) ridge type had no obvious undercut with more or less parallel buccal and lingual plates. Convex (C) type ridge had no undercut with wider base and narrower crest. Prevalence of each ridge type was calculated. Concavity angle was measured in degrees, by determining the angle between lines X and Y. Horizontal distance between point A and point B was labelled as linear concavity depth. Greater concavity had greater angle with lesser depth. Vertical distances from alveolar crest to point A (Vb) and inferior border of mandible to point A (Vc) were also measured to determine the vertical location of concavity. Data was analyzed using SPSS version 24. Data was not normally distributed, hence non-parametric tests were selected. Descriptive statistics were calculated. Post-stratification Mann-Whitney U test was used for effect modifiers such as gender, while Kruskal-Wallis test was used to compare study parameters between groups.  $P < 0.05$  was taken as significant.

#### RESULTS:

Of the 75 selected patients, 36 (48%) were male and 39 (52%) were female. Mean bone width (Wa) was found to be  $7.15 \pm 1.62$  mm while a mean concavity depth of  $1.17 \pm 1.40$  mm was observed. Table 1 illustrates the mean and standard deviations of all study parameters. Majority (46.7%) of the subjects presented with undercut type ridge. Figure 2 highlights the frequency of different types of ridges observed. No significant difference was observed between males and females for any study parameter (Table 2). Table 3 highlights the difference in study parameters between different ridge types.

#### DISCUSSION:

In addition to ridge height and width, lingual concavity depth and angle are important factors to be considered in implant placement. They help to place and align the drill properly during osteotomy.<sup>20</sup> In the present study, mean mandibular lingual concavity depth was  $1.17 \pm 1.40$  mm

Table 1: Descriptive statistics of study parameters (N=75)

Study Parameter	Mean± SD	Median
Bone width Wa	7.15±1.62	6.9
Bone width Wb	10.97±1.19	10.8
Bone Height Va	14.36±2.54	14.7
Concavity angle	31.78±35.97	60.2
Concavity depth	1.17±1.40	1.2
Vertical undercut position Vb	3.04±3.68	9.9
Vertical undercut position Vc	8.42±9.54	10.5

Table 2: Comparison of study parameters between Males and Females

Study Parameter	Gender	Mean Rank	P value (Mann-Whitney U test)
Bone width Wa	Male	38.33	.898
	Female	37.69	
Bone width Wb	Male	39.65	.527
	Female	36.47	
Bone Height Va	Male	37.38	.811
	Female	38.58	
Concavity angle	Male	34.64	.163
	Female	41.10	
Concavity depth	Male	36.33	.489
	Female	39.54	
Vertical undercut position Vb	Male	34.44	.139
	Female	41.28	
Vertical undercut position Vc	Male	36.97	.670
	Female	38.95	

Table 3: Comparison of study statistics between subjects with different ridge types

Parameter	Ridge Type	N	Mean Rank	P value (Kruskal-Wallis Test)
Bone Width Wa	Undercut	35	57.77	<.001
	Parallel	16	28.28	
	Convex	24	15.65	
	Total	75		
Bone Width Wb	Undercut	35	20.26	<.001
	Parallel	16	46.59	
	Convex	24	58.15	
	Total	75		
Bone Height Va	Undercut	35	36.17	0.792
	Parallel	16	39.38	
	Convex	24	39.75	
	Total	75		
Concavity Angle	Undercut	35	58.00	<.001
	Parallel	16	20.50	
	Convex	24	20.50	
	Total	75		
Concavity Depth	Undercut	35	58.00	<.001
	Parallel	16	20.50	
	Convex	24	20.50	
	Total	75		
Vertical Undercut Position Vb	Undercut	35	58.00	<.001
	Parallel	16	20.50	
	Convex	24	20.50	
	Total	75		
Vertical Undercut Position Vc	Undercut	35	58.00	<.001
	Parallel	16	20.50	
	Convex	24	20.50	
	Total	75		

(median: 1.2 mm). Similar results have been reported by Panjnoush et.al.<sup>21</sup> who found a mean lingual concavity depth of  $1.3 \pm 1.54$  mm, and by Kamburoglu et.al. who also reported a mean concavity depth of 1.3 mm.<sup>22</sup> However, the results of the present study differ from those of Chan et.al. who reported a mean concavity depth of 2.4 mm.<sup>8</sup> Parnia et.al. also reported a greater mean concavity depth

Figure 1: Different measurements taken of mandibular cross-sectional morphology

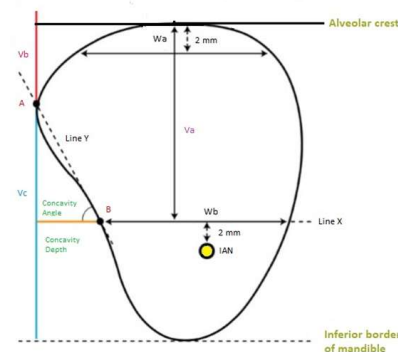
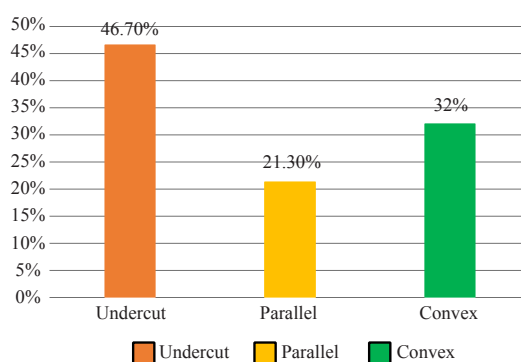


Figure 2: Types of mandibular ridges



of  $2.6 \pm 0.85$  mm.<sup>20</sup> These differences may be attributed to a difference in measurement methods as well as to differences in ethnicity of the study population.

In the present study, 56% (n=42) of subjects showed mandibular lingual concavity depth more than zero, which was lower than Chan et.al. study (66%) and Nickenig et.al. (68%).<sup>8, 10</sup> In the study by Chan et.al.<sup>8</sup> subjects were classified into three types C (convex), P (parallel), U (undercut) according to ridge morphology, where a higher frequency (66%) of undercut ridges was encountered. The same morphologic classification was used in this current study and undercut ridges were found to be more frequent (46.7%, n=35).

No significant difference was observed between males and females in term of ridge morphology in this study. The findings are endorsed by those of Chan et.al.<sup>8</sup> Salemi et.al.,<sup>9</sup> and Yoon et.al.<sup>23</sup> However, conflicting results have been reported by Zhang et.al. who found a significant difference in mandibular width between males and females. The researchers measured the distance between external surface of buccal and lingual cortical plates, and this method of measurement is perhaps the reason for varying results.

Undercut ridges present an increased risk of lingual perforations during implant placement. The consequences of lingual plate perforation vary depending upon the site of the perforation. In anterior mandible, lingual perforation

can damage submental and sublingual arteries, resulting in massive, potentially fatal hemorrhage.<sup>24</sup> Apart from the submandibular gland and lymph nodes, the sub-mandibular space, on the contrary, is devoid of any vital structures. Lingual nerve can be damaged if the lingual plate is perforated above the mylohyoid ridge.<sup>19</sup> If implant is exposed in the oral cavity, persistent inflammation or infection may develop and can lead to more serious complications. Such infections although do not develop immediately, but their insidious nature requires careful prior treatment planning.

Conventionally, prospective implant sites have been assessed using periapical and panoramic radiographs. Since these techniques are two-dimensional, they fail to provide adequate accurate information about bone width i.e. the bucco-lingual dimension.<sup>9</sup> In contrast, CBCT offers benefits of low radiation exposure, high resolution and accuracy, relative cost-effectiveness and less technique sensitive.<sup>1,17,20</sup> As lingual concavity poses a serious risk of perforation during implant placement, it is prudent to use CBCT to assess mandibular ridge morphology, quality and quantity prior to implant surgery.<sup>17</sup> Such careful treatment planning can be instrumental in preventing intra- and post-operative complications.

#### CONCLUSION:

A mean concavity depth of  $1.17 \pm 1.40$  mm was found in the study sample. Of the three ridge types, undercut ridge had the highest frequency followed by convex and parallel. No significant association was found between any mandibular ridge morphological parameter and gender. Pre-operative assessment of implant site using CBCT can serve as a reliable method to avoid complications

#### REFERENCES:

1. Misch CE. Dental implant prosthetics. 2nd ed. St. Louis, Missouri: Mosby; 2014.
2. Sheikh MA, Shafiq S, Syed AM, Riaz M. Success & Evaluation of Dental Implant Patients at Islamic International Dental College & Hospital. *Pak Oral Dent J* 2012;32(1):10-5.
3. Misch K, Wang HL. Implant surgery complications: etiology and treatment. *Implant Dent* 2008;17(2):159-68.
4. McDermott NE, Chuang SK, Woo VV, Dodson TB. Complications of dental implants: identification, frequency, and associated risk factors. *Int J Oral Maxillofac Implants* 2003;18(6):848-55.
5. Misch CE, Bidez MW. Implant-protected occlusion: A biomechanical rationale. *Compend Contin Educ Dent* 1994;15:1330-34.
6. Reilly DT, Burstein AH. The elastic and ultimate properties of compact bone tissue. *J Biomech* 1975;8:393-405.
7. Lin CL, Wang JC, Ramp LC, Liu PR. Biomechanical response of implant systems placed in the maxillary posterior region under various conditions of angulation, bone density, and loading. *Int J Oral Maxillofac Implants* 2008;23:57-64.
8. Chan HL, Brooks SL, Fu JH, Yeh CY et.al. Cross-sectional analysis of the mandibular lingual concavity using cone beam computed tomography. *Clin Oral Impl Res* 2011;22:201-6.

9. Salemi F, Shokri A, Forouzandeh M, Karami M, Khalili Z. Mandibular Lingual Concavity: A Cross-sectional Analysis using Cone Beam Computed Tomography. *J Clin Diagn Res* 2018;12(10):37-41.
10. Nickenig HJ, Wichmann M, Eitner S, Zoller JE, Kreppel M. Lingual concavities in the mandible: A morphological study using cross-sectional analysis determined by CBCT. *J Craniomaxillofac Surg Radiol Anat* 2015;37:1209-15.
11. Zarb G. The promise of osseointegration: Two decades later. *Clinical implant dentistry and related research* 2002;4:57-9.
12. Quirynen M, Mraiwa N, Steenberghe DV, Jacobs R. Morphology and dimensions of mandibular jaw bone in the interforaminal region in patients requiring implants in distal areas. *Clin oral Impl Res* 2003;14:280-5.
13. Greenstein G, Cavallaro J, Romanos G, Tarnow D. Clinical recommendations for avoiding and managing surgical complications associated with implant dentistry: A review. *J Periodontol* 2008;79:1317-29.
14. Greenstein G, Cavallaro J, Tarnow D. Practical application of anatomy for the dental implant surgeon. *J Periodontol* 2008;79:1833-46.
15. Lekholm U, Zarb GA. Tissue-Integrated Prostheses. Osseointegration in Clinical Dentistry. In: Branemark PI, Zarb GA, Albrektsson T, editors. *Tissue-Integrated Prostheses Osseointegration in Clinical Dentistry*. Chicago: Quintessence; 1985. p. 199-209.
16. Tepper G, Hofschneider UB, Gahleitner A, Ulm C. Computed tomographic diagnosis and localization of bone canals in the mandibular interforaminal region for prevention of bleeding complications during implant surgery. *Int J Oral Maxillofac Implants* 2001;16(1):68-72.
17. Kaeppeler G, Mast M. Indications for cone-beam computed tomography in the area of oral and maxillofacial surgery. *Int J Comput Den* 2012;15(4):271-86.
18. Kaawamata A, Arijji Y, Langlais RP. Three dimensional computed tomography imaging in dentistry. *Dent Clin North Am* 2000;44:395-410.
19. Chan HL, Leong DJ, Fu JH, Yeh CY, Tatarakis N, Wang HL. The significance of the lingual nerve during periodontal/implant surgery. *J Periodontol* 2010;81(3):372-7.
20. Parnia F, Fard EM, Mahboub F, Hafezeqoran A, Gavvani FE. Tomographic volume evaluation of submandibular fossa in patients requiring dental implants. *Oral Surg Oral Med Oral Pathol Oral Radiol Endod* 2010;109:e32-6.
21. Panjnoush M, Eil N, Kheirandish Y, Mofidi N, Shamshiri AR. Evaluation of the concavity depth and inclination in jaws using CBCT. *Caspian J Dent Res* 2016;5:17-23.
22. Kamburoglu K, Acar B, Yuksel S, Paksoy CS. CBCT quantitative evaluation of mandibular lingual concavities in dental implant patients. *Surg Radiol Anat* 2015;37(10):1209-15.
23. Yoon TY, Patel M, Michaud RA, Manibo. AM. Cone beam computerized tomography analysis of the posterior and anterior mandibular lingual concavity for dental implant patients. *The Journal of oral implantology* 2017;43(1):12-8.
24. Tomljenovic B, Herrmann S, Filippi A, Kühl S. Life-threatening hemorrhage associated with dental implant surgery: a review of the literature. *Clin Oral Impl Res* 2016;27(9):1079-84