

## ORIGINAL ARTICLE

# Clinical Presentation of Malignant Tumours of Tonsil and its Association with Unilateral Enlarged Tonsil in Different Age Groups

Tallat Najeeb<sup>1</sup>, Raja Muhammad Shoaib<sup>2</sup>, Nayyer Ayub<sup>3</sup>

### ABSTRACT:

**Objective:** To determine different clinical presentations in tonsil malignancy with unilateral enlarged tonsil (UET) in different age groups.

**Materials and Methods:** This descriptive cross sectional study was carried out from 2007 to 2014 in Social Security Hospital Islamabad (allied with Islamabad Medical and Dental College) and in Holy Family Hospital Rawalpindi. 80 patients underwent tonsillectomy suspected of tonsil tumour with tonsil asymmetry. In Group I patients were of 3-12 years and in group II, of 13 and above. Clinical assessment was done for any Regional and systemic disease. After tonsillectomy, difference in tonsil size was recorded on gross examination and then sent for histopathology. Statistical evaluation was done by using SPSS 16.

**Results:** In group I predominant symptom was bilateral (B/L) cervical lymph node enlargement, 32(82%) along with UET. Majority of patients (82.5%) with clinically enlarged tonsil also showed enlargement in gross. Reactive hyperplasia was seen in 2 and lymphoma in 7 on histopathology. In group II Predominant clinical features were cervical lymphadenopathy, recurrent sore throat, headache, nasal obstruction, cough, earache and postnasal drip. 87.5 % of clinically enlarged tonsil showed enlargement in gross examination. Histopathology revealed lymph adenitis in 30, Squamous cell carcinoma (SCC) in 5 and B cell lymphoma in 2.

**Conclusion:** Tonsillectomy must be done in UET to rule out malignant tumour of tonsil if accompanied by specific symptoms that could lead to tonsillar malignancy especially in adults.

**Keywords:** Unilateral tonsil enlargement, Hyperplasia, Neoplasm, Clinical presentation, Prevalence

### INTRODUCTION:

Palatine tonsils (PTs) are important lymphoid tissue of Waldeyer's ring, symmetrically located in the tonsillar fossae in oropharynx.<sup>1,2</sup> Unilateral enlarged tonsils (UET) is a common clinical finding in otorhinology caused by repeated tonsillitis, chronic tuberculosis, actinomycosis, anatomical variations in the tonsillar fossa depth, benign and malignant tumors.<sup>3,4,5</sup> Lymphomas are the most common malignant tumors of the head and neck in the pediatric population<sup>6</sup> and non-Hodgkin lymphoma (NHL) is the most common type among lymphomas.<sup>6,7</sup> The most common presentation of NHL is painful cervical lymphadenopathy along with UET. Extra nodal involvement is more common in NHL.<sup>8</sup> In adults squamous cell carcinoma is found to be commonest

type that usually presents with non-healing ulcer over the tonsil<sup>9</sup>. It has been standard practice to perform tonsillectomy and it is one of the definite indications for surgery especially when UET is associated with leading diagnostic tonsillectomy for histopathological purposes to exclude malignancy when tonsillar asymmetry is symptoms.<sup>2,10,11</sup> It is rare to find malignancy in enlarged tonsil if UET has been the only indication for tonsillectomy without any leading symptom especially in children<sup>12,13</sup>. Tonsillectomy when indication is asymmetry accompanied by leading symptoms, could be an important and beneficial step in the management of such cases. This study aims to assess the frequency of malignancy in patients with UET having different clinical symptoms leading to suspicious of tonsillar malignancy both in children and this may lead to early diagnosis of malignancies and start of early treatment and will have positive impact on the progression and survival rates.<sup>3,11,12</sup>

### MATERIALS AND METHODS:

This descriptive cross sectional study was carried out from 2007 to 2014 in Social Security Hospital Islamabad (allied with Islamabad Medical and Dental College) and in Holy Family Hospital Rawalpindi. A total of 80 patients were studied with UET along with specific symptoms; recurrent throat infections, nasal obstruction, post nasal drip (PND), Odynophagia, ear ache, headache, cervical lymphadenopathy, lump in neck and ulcer over tonsil leading to suspicious of malignancy. They underwent tonsillectomy for purpose of histological examination from 2007 to 2014 in above mentioned institutes. Sampling was done by non-probability convenient sampling technique. Patients were divided into two groups according to their age. In group I, pediatric group; included patients between age group 3-12 years

#### ✉ Dr. Tallat Najeeb

Associate Professor  
Department of ENT  
Islamabad Medical and Dental College  
Islamabad  
Email: tallatnajeeb@yahoo.com

#### ✉ Dr. Raja Muhammad Shoaib

Assistant Professor  
Department of ENT  
Islamabad Medical & Dental College  
Islamabad

#### ✉ Dr. Nayyer Ayub

Assistant Professor  
Department of ENT  
Islamabad Medical & Dental College  
Islamabad

Received: 09-06-2015

Revised: 24-07-2015

Accepted: 28-07-2015

and in group II, adult group; were of age 13 years and above. All the patients were assessed clinically for chronic sinusitis, recurrent tonsillitis, and ulcers over the tonsils, chronic nasal obstruction, dysphagia, PND, neck swelling, significant cervical lymphadenopathy and systemically like long standing fever, enlarged inguinal lymphnodes and hepatosplenomegaly. Only those patients presented with above mentioned symptoms with UET were included in study for biopsy purposes. Exclusion criteria included patients with no preoperative notes, where histological reports were not available, and patients having no clinical feature except UET, immune compromised patients, who had malignancy at other sites already diagnosed and patients who had received radiotherapy.

Any difference noticed between right and left sides was considered asymmetric. Patients' age, gender, right (R) and left (L) tonsil asymmetry in size, all clinical features, pathological results; gross pathology (width, depth, volume and height) and histopathology were recorded. Clinically enlarged tonsils were kept in three levels; mild difference (+1), moderate difference (+2) and marked difference (+3).

After doing bilateral tonsillectomy, difference was divided in three categories, +1; when difference in gross and clinical was <5mm, +2; was between 5-10mm, and in +3 cases was >10mm. t test was applied for clinically enlarged tonsils and actual tonsil size in gross pathology, P value was considered significant when it was < 0.05. Tonsils were sent for histopathology. In retrospective cases data was collected from record. All the data was recorded on a preformed Proforma. Statistical evaluation of results was done by using Window SPSS 16 and descriptive analysis was done.

**RESULTS:**

In group I number of patients were 40, age ranged from 3- 12 years, mean age was 7.5. 30 (75%) were male, 10 (25%) were female. Mild difference (+1) was noticed in 15(37%), 5 on right(R) and 10 on left(L) side, moderate (+2) in 10 (25%) 5 on R side and 5 on L side; marked difference (+3) was in 15(37.5%), 6 were of L side and 9 were on R side ( Table I).

Table: 1

Average of difference between clinical and pathological enlarged tonsil

Size of tonsil	Hypertrophy assessed clinically		Hypertrophy in gross pathology		Average	
	Group I	Group II	Group I	Group II	Group I	Group II
Mild (+1)	15	25	8	21		
Moderate (+2)	10	10	10	10	82.5%	87.5%
Marked (+3)	15	5	15	4		

In gross pathology, difference was noticed in volume,

height, width and length in 32 out of 40(80%), 8(53%) out of 15 cases of mild (+). All cases (100%) of moderate (+2) and marked (+3) enlargement showed valuable difference in size. Total average of difference in size in all cases was 82.5% (Table 1). t test was applied for clinically enlarged tonsils and actual tonsil size in gross pathology, P value <0.05. Predominant clinical feature was bilateral (B/L) cervical lymphadenopathy (32=80%). Other clinical features with average are shown in Table 2.

Table: 2

Clinical features in group I and II

Clinical features	Group I	Group II
B/L cervical lymphadenopathy	32(80%)	2(5%)
Recurrent sore throat	27(67%)	25(62%)
U/L cervical lymphadenopathy	20(50%)	30(75%)
Nasal obstruction(due to DNS or Adenoids)	17(42%)	1(2.5%)
PND	9(22%)	22(55%)
Abdominal symptoms	5(12.5%)	2(5%)
Headache	-----	9(22%)
Cough	-----	9(22%)
Earache	-----	10(25%)
Swelling neck	-----	4(45%)
Ulcer over tonsil	.....	4(10%)

Results of histopathology are shown in Figure 1. Only 4 out of 40 enlarged tonsil diagnosed as tumour, average was 10% (Figure 2). Chi-square test was applied for frequency, p value <.05, results were significant.

Figure: 1

Histopathology results in group I

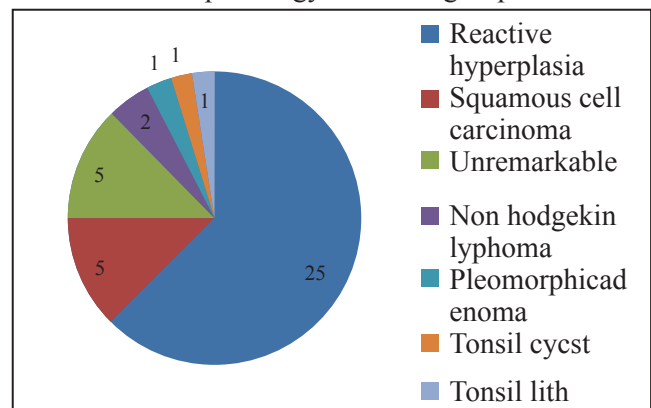
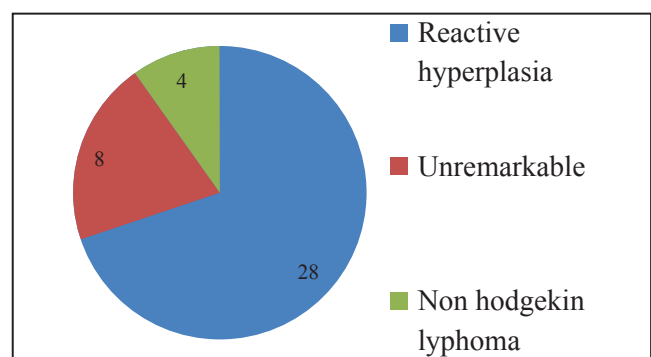


Figure: 2

Histopathology results in group II

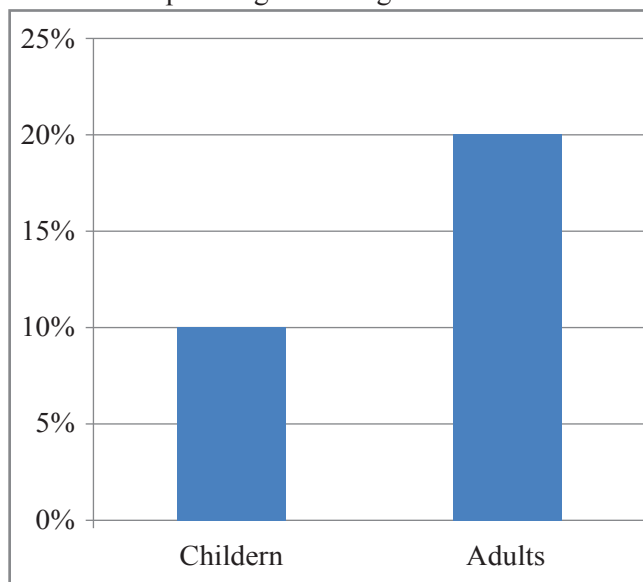


In group II number of patients were 40, age ranged from 13- 60 years, mean age was 36, 27 (75%) were male, 25 (67.5%) were female. Mild difference (+1) was noticed in 25(62.5%), 10 on right (R) and 15 on left (L) side, moderate (+2) in 10 (25%) 6 on R side and 4 on L side; marked difference (+3) was in 5(12.5%), 1 on L side and 4 on R side ( Table 1). In gross pathology after doing tonsillectomy, difference was noticed in volume, height, width and length in 35 out of 40(87.5%), 21 out of 25 cases (84%) of mild(+1) and all cases(100%) of moderate (+2) showed valuable difference in size. 4 cases (80%) of markedly enlarged tonsil (+3) showed difference in size. Total average of difference in size in all cases was 87.5% (35/40 as seen in Table 1). t test was applied for clinically enlarged tonsils and actual tonsil size in gross pathology, significant P value < 0.05. Predominant clinical feature was unilateral (U/L) cervical lymphadenopathy (30=75%). Combination of symptoms were seen. Other clinical features with average are shown in Table 2.

Histopathology of 25 (62.5%) tonsil specimens showed reactive hyperplasia, 5(12.5%) were diagnosed as squamous cell carcinoma, Non Hodgkin lymphoma in 2 (5%) and pleomorphic adenoma, tonsil cyst and tonsillith in each case (2.5%) as shown in figure 2. Histopathology of only 5(12.5%) enlarged tonsil was unremarkable, these were mainly from +1 group. 8 out of 40 (20%) enlarged tonsils were diagnosed as tumour (figure 3). Chi-square test was applied for frequency, p value <.05, results are significant.

Figure: 3

Frequency of malignancy in different age groups in pathological enlarged tonsil



## DISCUSSION:

Although unilateral enlargement may be due to anatomical variations, but may result from repeated tonsillitis, chronic tuberculosis, benign and malignant tumours of tonsil particularly if the patient presents with suspicious symptoms such as sore throat, ulcer or membrane over the tonsils, painful cervical

lymphadenopathy, or fever.<sup>4,5,11</sup>

If tonsillectomy is being done to rule out malignancy in enlarged tonsil, these clinical features are important<sup>12</sup>. Present study determines the frequency of malignancy in clinically UET accompanied by other clinical features.

In our study, 32 out of 40(80%) children and 35 out of 40(87.5%) adults with UET clinically showed actual enlargement in gross pathology after doing tonsillectomy. Most of the patients were from moderate to severely enlarged group.

Our study is comparable with one study performed in adults above 18 years of age with UET. 46 patients were assessed for UET, 28 out of 46(57.14%) showed actual difference in size when measured in gross specimens. It was noticed that pathological enlargement was usually seen in +2 and +3. Difference was seen only in few cases of +1 cases.<sup>6,13</sup>

In another study, 47 children with tonsil asymmetry were studied, no statistical difference in degree of asymmetry was found on clinical and pathological examination (p=0.5). A difference in depth of tonsillar fossa was identified. More accurate method to assess the size of tonsil is CT scan. After confirming the size of tonsil with CT scan clinician will be better able to counsel the patients regarding need to undergo tonsillectomy.<sup>14,15</sup> Actual tonsillar hypertrophy in gross after tonsillectomy was significant in both adults and children if there are leading clinical features such as enlarged cervical lymph nodes, nasal obstruction, PND, recurrent sore throat as compared to if UET has been the incidental finding. False results due to anatomical variation in depth of tonsillar fossa are more common if UET is not accompanied by other clinical features.<sup>9,12</sup>

In our study Predominant clinical feature in children with reactive hyperplasia were bilateral cervical lymphadenopathy, recurrent sore throat, adenoid hypertrophy, deflected nasal septum (DNS), postnasal drip (PND) along with UET. Abdominal symptoms (pain, inguinal lymph nodes and splenomegaly) were seen with UET where tonsillectomy specimen showed lymphomas.

In adults predominant symptoms with UET due to reactive hyperplasia were post nasal drip, U/L cervical lymphadenopathy. In patients with malignancy predominant symptoms were U/L cervical lymph node, earache, ulcer over tonsil and abdominal symptoms along with UET. We can compare our study with retrospective studies in which predominant symptoms in children with malignancy were UET with change in voice (muffled) nocturnal snoring, some episodes of apnea, nighttime awakenings, reduced appetite, weight loss, cervical lymphadenopathy and cough.<sup>9,16,17,18</sup> Tonsillar asymmetry, visible lesion or hard consistency upon palpation of the tonsil, unexplained loss of weight and the presence of cervical mass had been common

symptoms in adults with squamous cell carcinoma.<sup>9,18</sup> Symptoms of infection of the pharynx and tonsils, such as exudate in the tonsils, painful cervical adenopathy, PND or fever were common in UET with reactive hyperplasia in both adults and children<sup>9,16,19</sup>. Asymmetrical tonsils and suspicion of malignancy is one of the indications for tonsillectomy. The incidence of malignancy in patients undergoing tonsillectomy is low (approximately 2.5:10,000) if not associated with other important clinical symptoms.<sup>15,20,21</sup> Incidence increases if tonsil asymmetry is associated with suspicious clinical symptoms.<sup>2,20,21</sup> In a previous study, children undergoing surgery because of tonsillar asymmetry where the presence of enlarged cervical lymph nodes and abnormal appearance of the tonsils were additional risks factors, incidence was 20%. In one of previous study incidence of lymphoma in patients with UET without any other clinical symptom was 4%.<sup>13,22</sup> In our study frequency of malignancy in children was 10% and in adults was 20%. All of the patients presented with UET and different clinical features. While considering frequency we can compare our results with these previous studies.<sup>23,24,25</sup> The tonsillectomy is one of the most common surgeries in the world and a malignancy is generally connected to other clinical findings along with UET that may be confirmed by histopathology of all tonsillectomy specimens. This study proposes that tonsillectomy must be reserved for cases of suspicion and the tonsillar asymmetry is undoubtedly the main one.

## CONCLUSION:

Although a few patients with palatine tonsil asymmetry have malignancy but most of the patients with tonsillar malignancy have tonsillar asymmetry. Detailed examination of the oral cavity and neck is essential and only those patients of UET with other important clinical symptoms suggestive of malignancy should undergo tonsillectomy.

The histopathological review of all pieces of tonsillectomy is crucial especially where the patient has other associated symptoms that suggest a malignancy. A large scale multicenter study should be carried out to determine the frequency of malignancy in uneven enlarged tonsil.

## REFERENCES:

1. Ballin AC, Koerner HN, Ballin CH, Pereira R, Alcântara LJ, Taques GR et al. Palatine tonsils asymmetry: 10 years experience of the Otorhinolaryngology service of the clinical hospital of the Federal University of Paraná. *ArqInt Otorrinolaringol* 2011;15:67-71.
2. AlexandreCaixetaGuimarães;Guilherme Machado de Carvalho; ReinaldoJordãoGusmão. Tonsillar lymphoma in children with unilateral tonsillar enlargement. *RevistaPaulista de Pediatriapaul. pediatr.* 2012;30:84-9
3. Brodsky L, Poje CP. Tonsilite, tonsilectomiae aden-

- oidectomy. In: Bailey BJ, Johnson JT, editors. *Otorrinolaringologia: cirurgia de cabeça e pescoço*. 4th ed. Philadelphia: Lippincott Williams & Wilkins; 2009. p. 161-4.
4. Sturn-O'Brien AK, Hicks JM, Giannoni CM, Sulek M, Friedman EM. Optimal utilization of histopathologic: analysis of tonsil and adenoid specimens in the pediatric population. *Int J PediatrOtorhinolaryngol* 2010;74:161-3.
5. Sengupta S, Pal R. Clinicopathological correlates of pediatric head and neck cancer. *J Cancer Res Ther* 2009;5:181-5.
6. Tobias Gómez S, Palomar Asenjo V, BorràsPerera M, Pérez Hernández I, Ruiz Giner A, Palomar García V. Clinical significance of unilateral tonsillar enlargement. *ActaOtorrinolaringolEsp*2009;60:194-8.
7. Marcinow AM, Hall N, Byrum E, Teknos TN, Old MO, Agrawal A. Use of a Novel Receptor-Targeted (CD206) Radiotracer, 99mTc-Tilmanocept, and SPECT/CT for Sentinel Lymph Node Detection in Oral Cavity Squamous Cell Carcinoma: Initial Institutional Report in an Ongoing Phase 3 Study. *JAMA Otolaryngol Head Neck Surg.* 2013; 139(9):895-902.
8. Nelson R. Lymphoseek improves lymph node mapping in head and neck cancer. *Medscape Medical News.* September25,2013.Available at <http://www.medscape.com/viewarticle/811622>. Accessed October 1, 2013.
9. BrentuximabVedotin for Patients with Relapsed or Refractory Hodgkin's Lymphoma. *J Clin Oncol.* 2012; 30(18) :2183-9.
10. Meyer RM, Gospodarowicz MK, Connors JM, Pearcey RG, Wells WA, Winter JN, et al. ABVD alone versus radiation-based therapy in limited-stage Hodgkin's lymphoma. *N Engl J Med* 2012;366(5) :399-408.
11. Jemal A, Siegel R, Ward E, Hao Y, Xu J, Thun MJ. Cancer statistics, 2009. *CA Cancer J Clin.* 2009;59(4):225-49.
12. Cohan DM, Popat S, Kaplan SE, Rigual N, Loree T, Hicks Jr, WL. Oropharyngeal cancer: current understanding and management. *Current Opinion in Otolaryngology & Head and Neck Surgery.* 2009,17(2):88-94.
13. TallatNajeeb, RizwanUllah, Frequency of malignancy in Asymptomatic unilateral enlarged tonsils. *JRMC.* 2013, 17(2): Pages:262-4.
14. Dolev Y, Daniel SJ. The presence of unilateral tonsillarenlargement in patients diagnosed with palatine tonsil lymphoma: experience at a tertiary care pediatric hospital. *Int J PediatricOtorhinolaryngol.* 2008 ;72:9-12.
15. Ramar K. Asymmetric tonsillar enlargement and obstructive sleep apnea. *Sleep Medicine.* 2008, 9:209-10.
16. Shao CH, Huang SC, Hwang CF, Peng JP. Extraosseous Ewing sarcoma of the tonsil. *J Otolaryngol Head Neck Surg* 2012;41:35-7.
17. Agida S Adoga, Danle N Ma'an, Samuel I Nuhu. Is routine histopathology of tonsil Specimen necessary? *African Journal of Pediatric Surgery.*2011;3: 283-5.
18. YahavOron, Tal Marom, Eyal Russo, TiberiuEzri, Yehudah Roth. Don't overlook the complications of tonsillectomy. *Journal of family practice.*2010; 10:4-9.
19. Mehanna H, Paleri V, West CM. Head and Neck cancer Part 1: Epidemiology, presentation, and prevention. *BMJ.* 2010 ;20:341-4.
20. Kim L, King T, Agulnik M. Head and neck cancer: changing epidemiology and public health implications. *Oncology(Williston Park)J.* 2010;24:915-92.
21. Koç S, Uysal IO, Yaman H, Eyibilen A. KulakBurun BogazIhtisDerg.Histopathologic examination of routine

- tonsil and adenoid specimens: Is it a necessary approach? PubMed.2012; 22: 87-90.
22. Johansen J, Buus S, Loft A. Prospective study of 18FDG-PET in the detection and management of patients with lymph node metastases to the neck from an unknown primary tumor. *Head and Neck*. 2008; 4: 471-8.
  23. Katerini Spinou E, Kubba H, Konstantinidis I, Johnston A. Incidence of Unexpected malignancies in routine tonsillectomy specimen in Unilateral tonsillar enlargement and malignant tonsillar lymphoma] *Journal of Investigative Dermatology* advance online publication. 2012; 22: 579-81.
  24. Jarvis SJ, Giangrande V, Brennan PA. Mucoepidermoid Carcinoma Tonsil. *ACTA Otolaryngologica Italica*. 2013; 33(4):286-8.
  25. Christopher Skilbeck, Jean-Pierre Jeanon, Mary O Comell. Squamous Cell Carcinoma of Tonsillar remnant-Clinical presentation and oncological outcome *Head and Neck Oncol*. 2011; 19:3-4.

