

Comparative Study between Hemisoleus flap and Fascio-Cutaneous flap in Middle Third Lower Limb Infected Traumatic Wound

Zarish Daniel, Faizan Rahim, Fahad Soomro, Sumeet Kumar, Hiba Rashid, Abdul Khaliq Malik

ABSTRACT:

Objective: To compare the outcome of hemi-soleus and fascio-cutaneous in terms of flap viability, complications and stable coverage in infected traumatic wound on middle third lower limb

Study design & setting: Original article, Department of Plastic Surgery PIMS. The study has a period of six months from October 29, 2019, to April 29, 2020, under the approval of the Ethical Review Board (ERB) with reference number SZABMU/457

Methodology: The study aimed to investigate the outcomes of a specific intervention. The participant pool consisted of 120 individuals who met the predefined inclusion criteria, and each participant provided informed consent along with demographic information. The subjects were then randomly assigned to one of two groups. Subsequent to the surgical procedures, both groups were closely monitored in the post-operative phase, with meticulous recording of relevant data. The outcomes of interest were measured, and all information was systematically collected using a pre-designed Performa

Result: The mean age of the patients was 37.09 years, 109(90.83%) were male patients. Motor vehicle accident cause of injury was noted in 57(47.50%) patients and 5-7 cm size of defect was noted in 64(53.33%) patients. Few complications are found higher in Hemisoleus Flap group and few found higher in Fascio cutaneous flap group.

Conclusion: Results showed superior efficacy of hemi-soleus flaps, especially in open tibia fractures, with fewer complications. This supports their preference in managing such wounds, ensuring stable coverage and potential cost savings.

Key words: Wound Infection, Surgical Flaps, Trauma, Lower Extremity, Surgical Wound Dehiscence, Treatment Outcome

How to cite this Article:

Daniel Z, Rahim F, Soomro F, Kumar S, Rashid H, Malik AK. Comparative Study between Hemisoleus flap and Fascio-Cutaneous flap in Middle Third Lower Limb Infected Traumatic Wound. J Bahria Uni Med Dental Coll. 2023;14(3): 202-6 DOI: <https://doi.org/10.51985/JBUMDC2024358>

This is an Open Access article distributed under the terms of the Creative Commons Attribution Non Commercial License (<http://creativecommons.org/licenses/by-nc/4.0>) which permits unrestricted non commercial use, distribution and reproduction in any medium, provided the original work is properly cited.

INTRODUCTION:

One of the biggest causes of avoidable mortality is a car accident. It is estimated that 10 million motor vehicle accidents occur worldwide each year. Approximately 1.26 million people died in road traffic accidents (RTAs) worldwide in 2000, with South East Asia accounting for 35% of these fatalities. Every year, 10-15 million individuals are wounded in road traffic crashes, with poor and middle-income nations accounting for 90% of all RTC fatalities.

After researching the reasons for amputations among young men in India, the younger age groups from the teens to the 30s accounted for 46.2% of participants, thus making up the leading amputation age group

Besides chronic pain, inability to walk, high medical expenses, and unemployment, any exposed bone not covered by vascularized soft tissue is at risk for osteomyelitis, bone necrosis, and sepsis. As a result, The primary goal of lower limb reconstruction is to achieve durable soft-tissue coverage over a stable skeletal repair to enhance bone healing while maintaining sensory and motor functions. The flap is selected to minimize complications at the donor site while optimizing the function of the lower extremity.²

Because of the comparatively thin soft tissue envelope anteriorly, High-energy trauma, such as from motor vehicle

Zarish Daniel (Corresponding Author)
Senior Registrar, Department of Plastic Surgery
PIMS Hospital, Islamabad
Email: zarishbhatti22@gmail.com

Faizan Rahim
Senior Registrar, Department of Plastic Surgery
SHS of NUST
Email: dr.fazianrahim@gmail.com

Fahad Soomro
Registrar, Department of Plastic Surgery
PIMS Hospital, Islamabad
Email: fahad.soomro7@gmail.com

Sumeet Kumar
Medical Officer, Department Of Plastic Surgery,
PIMS Hospital, Islamabad
Email: sumeetmangwani@gmail.com

Hiba Rashid
Post Graduate Resident, Department of Plastic Surgery
PIMS Hospital, Islamabad
Email: hibba_rashid@yahoo.com

Abdul Khaliq Malik
Associate Professor, Department of Plastic Surgery
PIMS Hospital, Islamabad
Email: drabdulkhalek@yahoo.com

Received: 17-04-2024
Accepted: 10-07-2024

1st Revision: 17-05-2024
2nd Revision: 01-07-2024

accidents or severe falls, frequently results in complex open fractures of both the tibia and fibula, presenting significant challenges in terms of surgical management and long-term recovery. Gustilo type IIIB injuries are the most common in this part of the leg. The initial stage in lower extremity reconstruction is bone stabilization, either temporarily or permanently.³

The soleus muscle is a big, wide, bipennate muscle having separate neurovascular supply in both its lateral and medial heads. The Type II soleus muscle flap receives its blood supply from both large and small vascular pedicles. The dominant pedicle is from the muscular branches of the popliteal artery, which supply the uppermost part of the soleus muscle. Additionally, the proximal branches of the peroneal artery nourish the upper third of the muscle, complemented by the segmental and proximal branches of the posterior tibial artery.⁴

Fasciocutaneous flaps for middle third defect covering are often based on medial or posterolateral septocutaneous perforators, however flaps can alternatively be created without a discernible perforating artery. These are essentially random pattern fasciocutaneous flaps. The length: width ratio can be increased to 3: 1, or twice as large of random cutaneous flaps.⁵

Comparative study carried out in Lahore General Hospital from 2011-2018 using muscle and fasciocutaneous flaps both techniques demonstrated equally effective coverage of open tibial fractures.

In a review of 16 studies, 195 out of 241 patients who received gastrocnemius flaps (81%) experienced successful outcomes. Additionally, seven studies involving 84 patients who underwent fasciocutaneous flap coverage reported successful outcomes for over 90% of the patients. Moreover, four studies assessing delayed versus prophylactic soft tissue reconstruction in 144 patients found that up to 81% of these patients had successful outcomes⁷

Tsatter et al. conducted another study on pretibial defect covered by soleus flap surgery and reported that 18 (60%) patients had satisfactory outcomes. 7 (23.33%) of the instances were excellent, 3 (10%) were fair, and 2 (6.66%) were bad. In the end follow-up, the satisfying outcome (excellent and good) was 83.33%, but overall post-operative problems were 66.6%⁸. Post-traumatic wounds are highly susceptible to infection, particularly in developing countries such as Pakistan, making wound management more difficult. Despite the magnitude of this issue, there is a scarcity of literature to guide the most beneficial treatment options. My study aims to provide the most appropriate treatment option for the extremely large number of patients presenting with lower limb post-traumatic infected wounds.⁹

The study's goal is to determine the best feasible, stable covering with the fewest post-operative complications for post-traumatic lower limb infected wounds using hemi-

soleus and fasciocutaneous flaps.

METHODOLOGY:

The study conducted at the Department of Plastic Surgery spanning six months, from October 29, 2019, to April 29, 2020. With a meticulously determined sample size of 120 participants, equally divided into two groups, the study aimed to assess the efficacy of two surgical procedures for treating post-traumatic open infected wounds located in the middle segment of the leg that includes the area around the mid-shaft of the tibia and fibula. Employing a consecutive non-random sampling technique, participants meeting the inclusion criteria were enrolled, reflecting a pragmatic approach to participant recruitment within the designated timeframe.

The inclusion and exclusion criteria for this study were meticulously defined to ensure a focused and homogeneous participant group. Inclusion criteria encompassed individuals with post-traumatic open infected wounds located in the middle third of the leg, with a presentation timeframe ranging from immediate to three months. The study targeted a broad age range, specifically individuals aged 15 to 60 years, encompassing both genders. Participants were required to exhibit exposed bone, nerve, or tendon, necessitating soft tissue coverage, and have Gustillo type IIIB fractures. On the other hand, exclusion criteria aimed to refine the participant selection by excluding paraplegic, debilitated, or unfit individuals, as well as those with cardio-pulmonary problems. Additionally, patients with peripheral arterial disease, vascular structure involvement, and comorbidities such as diabetes, anemia, and hypertension were excluded. These stringent criteria were implemented to enhance the internal validity of the study, ensuring a more uniform and representative sample for the investigation of the specified post-traumatic wounds in the middle third of the leg. Group A was given hemisoleus flaps and Group B was given fasciocutaneous flap.

Ethical guidelines were strictly followed, with approval from the hospital's ethical committee and informed consent obtained from all participants. Random assignment to treatment groups was executed using a simple lottery method. Pre-operative assessments included comprehensive baseline investigations and tailored antibiotic administration based on culture and sensitivity testing results. Surgical procedures involved either a fascio-cutaneous flap or a hemi-soleus flap, chosen based on wound location. Close post-operative monitoring was implemented to promptly identify potential issues, with assessments of flap conditions, including color, turgor, and capillary refill time, conducted at specified intervals.

Post-operative complications such as flap dehiscence, necrosis, epidermolysis, infection, hematoma, and seroma formation were systematically documented. Evaluation of stable coverage occurred during follow-up intervals at 1

week, 2 weeks, 6 weeks, and 2 months post-operatively, ensuring a comprehensive assessment of flap conditions and outcomes. Data analysis utilized SPSS version 20, with critical numerical variables such as age, time elapsed since trauma, and defect size examined. Various patient-related variables including cause of injury and type of fracture were considered. Post-operative sequelae were thoroughly evaluated at specific time intervals, with statistical analysis performed to determine significant differences between the treatment groups.

A significance level of $p < 0.05$ was set, ensuring robust and interpretable results in line with the study's objectives. This comprehensive approach to data collection, analysis, and statistical testing aimed to provide a thorough investigation of variables, contributing to a robust understanding of outcomes and influencing factors within the context of the study.

RESULTS:

At 24th hour in group A the Seroma formation was noted in 7(11.7%) patients while in group B the Seroma formation was noted in 17(28.3%) patients (p -value=0.022). AT 48th hour follow up there is statistically insignificant difference was found between the Seroma formation and there is no statistically significant difference (p -value = 0.306) in seroma formation between groups A and B. Both groups have lower rates of seroma formation compared to the 24th hour. Group A has a rate of 11.7%, and Group B has 18.3%. The overall seroma formation at 48 hours is 15.0%. **Group A=Hemisaleus Flap** In group A at 5th day, flap necrosis occurred in 6 out of 60 patients (10%), while in group B, it was observed in 7 out of 60 patients (11.7%). Partial Flap necrosis was not detected in any patients in group A, whereas in group B, it was noted in 6 out of 60 patients (10%) (p -value=0.022). According to the results infection rates on the 5th day showed no significant difference between Group A (21.7%) and Group B (28.3%), with a p -value of 0.399. However, Group B experienced significantly higher rates of hematoma at the 24th hour (65.0% vs. 43.3%, p -value=0.017) and ulcer formation on the 5th day (51.7% vs. 33.3%, p -value=0.042) compared to Group A, indicating higher complication rates in Group B. Figure 1 Out of 120 patients motor vehicle accident (MVA) cause of injury was noted in 57(47.50%) patients, injury due to run over noted in 25(20.83%) patients, injury due to fall and firearm related injuries (FAI) was noted in 13(10.83%) patients respectively and injury due to work was noted in 12(10%) patients.

Group A= Hemisaleus Flap Among group A injury due to motor vehicle accident (MVA) noted in 33(57.9%) patients, injury due to fall and firearm-related injuries (FAI) was noted in 7(53.8%) patients respectively

DISCUSSION :

This study was conducted at the Department of Plastic Surgery PIMS to compare the outcome of hemi-soleus and

Table 1: Comparison of seroma formation at 24th, & 48th hour between study groups

Seroma formation		Study Groups		Total	p-value	
		A	B			
24 th hours	Yes	7 11.7%	17 28.3%	24 20.0%	0.022	
	No	53 88.3%	43 71.7%	96 80.0%		
48 th hours	Yes	7 11.7%	11 18.3%	18 15.0%		0.306
	No	53 88.3%	49 81.7%	102 85.0%		

Table 2: Comparison of flap dehiscence and necrosis at 5th days between study groups

Seroma formation		Study Groups		Total	p-value
		A	B		
Flap Dehiscence	Yes	6 10.0%	12 20.0%	18 15.0%	0.125
	No	54 90.0%	48 80.0%	102 85.0%	
Flap Necrosis	Partial	0 0.0%	6 10.0%	6 5.0%	0.022
	Yes	6 10.0%	7 11.7%	13 10.8%	
	No	54 90.0%	47 78.3%	101 84.2%	

Table 3: Comparison of infection and ulcer formation at 5th days and hematoma at 24th hour between study groups

			Study Groups		Total	p-value
			A	B		
Infection	5 th day	Yes	13 21.7%	17 28.3%	30 25.0%	0.399
		No	47 78.3%	43 71.7%	90 75.0%	
Hematoma	24 th hour	Yes	26 43.3%	39 65.0%	65 54.2%	0.017
		No	34 56.7%	21 35.0%	55 45.8%	
Ulcer formation	5 th day	Yes	20 33.3%	31 51.7%	51 42.5%	0.042
		No	40 66.7%	29 48.3%	69 57.5%	

fascio-cutaneous in terms of flap viability, complications and stable coverage in infected traumatic wound on middle third lower limb.

According to the current study the distribution of injury causes among patients, with motor vehicle accidents (MVA) being the predominant cause at 47.50%, followed by being run over at 20.83%, and falls at 10.83%. Other causes include FAI (10.83%) and work-related injuries (10.00%) Lower

Figure 1: Frequency distribution of cause of injury

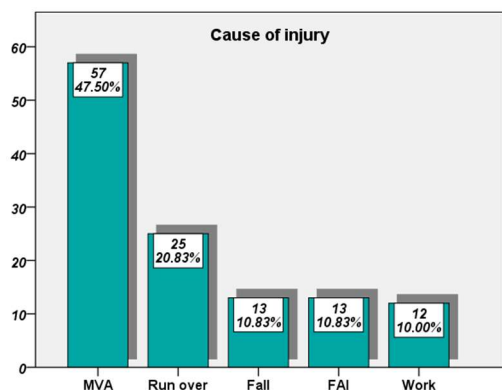
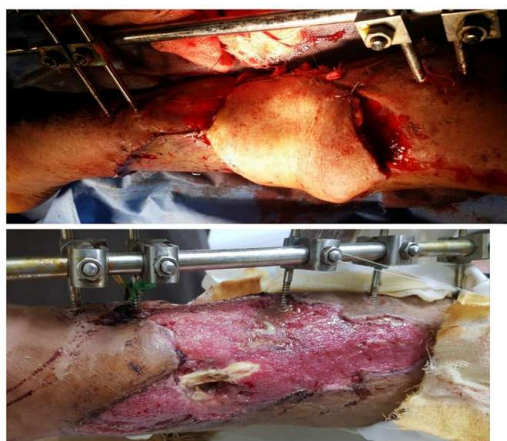

Figure 2: Fasciocutaneous flap in traumatic middle third lower limb



limb trauma ranks among the prevalent injuries in both traffic and workplace accidents. Following trauma, bone exposure often occurs, necessitating immediate coverage of these defects to mitigate the risk of osteomyelitis. Open fractures of the tibia represent one of the most frequently occurring long bone fractures and exhibit a bimodal age distribution. Typical complications following the treatment of open fractures include infection, malunion, and nonunion. Despite advancements in trauma management, open fractures continue to present a significant therapeutic challenge for medical professionals.^{10,11}

In the current study at the 24-hour mark, group A showed a seroma formation rate of 11.7% (7 patients), while group B had a notably higher rate of 28.3% (17 patients), resulting in a statistically significant difference with a p-value of 0.022. However, by the 48-hour follow-up, the difference in seroma rates between the two groups was not statistically significant, with a p-value of 0.306. At this time, the rates had decreased in both groups, with group A maintaining a rate of 11.7% and group B at 18.3%, leading to an overall rate of 15.0% at 48 hours. A meta-analysis on the effectiveness of flap fixation in preventing seroma formation post-mastectomy revealed significant results. The study showed

that patients undergoing flap fixation experienced a lower rate of seroma formation compared to those without flap fixation (22.41% vs. 43.61%, respectively, with a significant p-value of 0.001)¹².

A wide array of options have been outlined, spanning from local fasciocutaneous or muscle flaps to pedicled or free perforator flaps, as well as combined flaps and composite tissue constructs.^{13,18} In this study hemi-soleus flap showed low complication rate and more effective than to fascio-cutaneous flap in infected traumatic wounds on middle third of leg, below are discussions on some of the studies, outlining their findings as. Comparative study carried out in Lahore General Hospital from 2011-2018 using muscle and fasciocutaneous flap showed coverage of open tibial fractures by both techniques, are equally effective.⁶ In a study conducted on the coverage of pretibial defects using the soleus muscle flap, outcomes for 30 cases were assessed: 18 (60%) were rated as excellent, 7 (23.33%) as good, 3 (10%) as fair, and 2 (6.66%) as poor. The overall satisfaction rate, combining excellent and good outcomes, was 83.33%, with post-operative complications reported in 66.6% of cases. In another research by Luis Mata Ribeiro et al., the hemisoleus flap was evaluated for its effectiveness in covering defects in the middle to lower third of the leg. The study concluded that the hemisoleus flap is a highly effective treatment option, offering stable reconstruction with minimal morbidity and cost savings, thus presenting a valuable alternative to free flap reconstruction. According to Surasak et al all flaps survived without complications. Mean union time for fractures was 19.7 weeks¹⁹⁻²¹.

CONCLUSION:

In summary, this study conducted at the Department of Plastic Surgery, PIMS, aimed to assess the comparative outcomes of hemi-soleus and fascio-cutaneous flaps for addressing infected traumatic wounds in the middle third of the lower limb, particularly open fractures of the tibia. The study discerned that the hemi-soleus flap exhibited superior efficacy with a lower complication rate compared to the fascio-cutaneous flap in managing these specific traumatic wounds. In conclusion, the findings support the preferential use of the hemi-soleus flap as a viable treatment option for infected traumatic wounds in the specified lower limb region²⁰. This flap not only ensures robust viability and stable coverage but also holds potential for minimizing morbidity and costs in comparison to alternative reconstructive approaches.

Authors Contribution:
 | **Zarish Daniel:** Data compilation
 | **Faizan Rahim:** Concept of research, Introduction write up
 | data collection
 | **Fahad Soomro:** Data compilation
 | **Sumeet Kumar:** Write up and editing of article
 | **Hiba Rashid:** Data collection and article write up
 | **Abdul Khaliq Malik:** Data collection

REFERENCES:

1. Pooja GD, Sangeeta L. Prevalence and aetiology of amputation in Kolkata, India: A retrospective analysis. *Hong Kong Physiotherapy Journal*. 2013;31(1):36-40. DOI: 10.1016/j.hkpj.2012.12.002
2. Zeiderman MR, Pu LL. Contemporary approach to soft-tissue reconstruction of the lower extremity after trauma. *Burns & Trauma*. 2021;9(3): 024-28. DOI: <https://doi.org/10.1093/burnst/ktab024>
3. Palm VF, Hoogendoorn JM, Verhage SM. The role of fibula fixation in combined distal-third tibia and fibula fractures: a systematic literature review. *Archives of Orthopaedic and Trauma Surgery*. 2024 Jan;144(1):219-28.
4. Atia A, Vernon R, Pyfer BJ, Shammas RL, Hollenbeck ST. The essential local muscle flaps for lower extremity reconstruction. *Journal of Reconstructive Microsurgery*. 2020 Apr 17;37(01):089-96. DOI: 10.1055/s-0040-1709480
5. Falola RA, Rodriguez-Unda NA, Lombana NF, Altman AM, Saint-Cyr MH. Pudendal Artery Perforator Flap and Other Reconstructive Options in Perineal-Pelvic Reconstruction. *Perineal Reconstruction: Principles and Practice*. 2023 Apr 29(4):129-152.
6. Murtaza ME, Sajjad YA, Aslam MA. Comparison of outcome in coverage of open fractures of Tibia with pedicled fasciocutaneous flaps and muscle flaps with overlying graft in patients presenting to Plastic Surgery Department, Lahore General Hospital, Lahore. *PJMHS*. 2019;13(1):153-6.
7. Coombs DM, Churchill J, Cartwright P, Chughtai M, Sultan AA, Samuel LT, Moskal JT, Hendrickson MF, Mont MA. Soft tissue reconstruction for deep defects over a complicated total knee arthroplasty: a systematic review. *The Journal of Knee Surgery*. 2020 Jul;33(07):732-44. DOI: 10.1055/s-0039-1684012
8. Mavrouli M, Mavroulis S, Lekkas E, Tsakris A. The impact of earthquakes on public health: A narrative review of infectious diseases in the post-disaster period aiming to disaster risk reduction. *Microorganisms*. 2023 Feb 7;11(2):419. DOI: doi.org/10.3390/microorganisms11020419
9. Naem Jagani DL, Nambiar S, D'souza JJ, Borana C, Shah N. Functional outcome of primary flap coverage and bony fixation of severe open fractures: A prospective observational study.
10. Chan JK, Harry L, Williams G, Nanchahal J. Soft tissue reconstruction of open fractures of the lower limb: muscle versus fasciocutaneous flaps. *Plastic and reconstructive surgery*. 2012;130(2):284e. DOI: 10.1097/PRS.0b013e3182589e63
11. Economides JM, DeFazio MV, Golshani K, Cinque M, Anghel EL, Attinger CE, et al. Systematic review and comparative meta-analysis of outcomes following pedicled muscle versus fasciocutaneous flap coverage for complex periprosthetic wounds in patients with total knee arthroplasty. *Archives of plastic surgery*. 2017;44(2):124. DOI: 10.5999/aps.2017.44.2.124
12. Velotti N, Limite G, Vitiello A, Berardi G, Musella M. Flap fixation in preventing seroma formation after mastectomy: an updated meta-analysis. *Updates in Surgery*. 2021 Aug;73:1307-14.
13. Adam R, Watson S, Jarratt J, Noble J, Watson J. Outcome after flap cover for exposed total knee arthroplasties. A report of 25 cases. *The Journal of bone and joint surgery British volume*. 1994;76(5):750-3.
14. Andres LA, Casey WJ, Clarke HD. Techniques in soft tissue coverage around the knee. *Techniques in Knee Surgery*. 2009;8(2):119-. DOI: <https://doi.org/10.1097/BTK.0b013e3181a7eae>
15. Tiengo C, Macchi V, Vigato E, Porzionato A, Stecco C, Azzena B, et al. Reversed gracilis pedicle flap for coverage of a total knee prosthesis. *JBJS*. 2010;92(7):1640-6. DOI: 10.2106/JBJS.I.00195
16. Jung JA, Kim YW, Cheon YW. Reverse gracilis muscle flap: an alternative means of skin coverage for recurrent infection after TKA. *Knee Surgery, Sports Traumatology, Arthroscopy*. 2013;21(12):2779-83. DOI: <https://doi.org/10.1007/s00167-012-2210-4>
17. Demirseren ME, Efendioglu K, Demiralp CO, Kilicarslan K, Akkaya H. Clinical experience with a reverse-flow anterolateral thigh 18. Tolhurst DE, Haeseker B, Zeeman RJ, Barclay T. The development of the fasciocutaneous flap and its clinical applications. *Plastic and reconstructive surgery*. 1983;71(5): 606. DOI: doi.org/10.1016/j.bjps.2011.06.047
18. Rovere G, Smakaj A, Calori S, Barbaliscia M, Ziranu A, Pataia E, Maccauro G, De Mauro D, Liuzza F. Use of muscular flaps for the treatment of knee prosthetic joint infection: A systematic review. *Orthopedic Reviews*. 2022;14(2). DOI: <https://doi.org/10.52965/2F001c.33943>
19. Satter T, Khan MN, Awwal R. Soleus muscle flap for the coverage of pre-tibial defect of middle third of leg. *Bangladesh Journal of Plastic Surgery*. 2013;4(1):10-5. DOI: <https://doi.org/10.3329/bdjps.v4i1.18685>
20. Ribeiro LM, Meireles RP, Brito IM, Costa PM, Rebelo MA, Barbosa RF, et al . Comparison of outcomes in immediate implant-based breast reconstruction: acellular dermal matrix versus inferior dermal flap. *Archives of Plastic Surgery*. 2022 Mar;49(02):158-65. DOI: 10.1055/s-0042-1744404
21. Surasak, Jitprapaikulsarn., Kriangkamol, Benjawongsathien., Chawanon, Patamamongkonchai., et al . Combined medial gastrocnemius and hemisoleus flap: a reproducible alternative for open tibial fractures complicated with large or double soft tissue defects. *European Journal of Orthopaedic Surgery and Traumatology*, (2021). DOI: 10.1007/S00590-020-02772-6