

## Oral Potentially Malignant Disorders: A Comprehensive Review of Diagnostic Approaches and Management Strategies

Angabeen Anjum, Nauman Sheikh

### ABSTRACT:

Oral potentially malignant disorders (OPMDs) encompass a group of conditions that have an increased risk of progressing to oral cancer. Timely diagnosis and effective management of these disorders play a crucial role in preventing malignant transformation and improving patient outcomes. This review article provides a comprehensive overview of the diagnostic approaches and management strategies for OPMDs. It discusses the current understanding of OPMDs, highlights the various diagnostic methods available, and explores the evolving landscape of management options. The aim of this review is to enhance the knowledge and awareness of healthcare professionals involved in oral pathology and promote effective decision-making in the diagnosis and management of OPMDs.

A thorough understanding of diagnostic approaches and management strategies for oral potentially malignant disorders is essential for dental and medical professionals involved in oral pathology. This review article provides a comprehensive overview of the topic, highlighting the importance of early detection, risk assessment, and interdisciplinary collaboration.

**Keywords:** Erythroplakia, Leukoplakia, Oral lichen planus, Oral potentially malignant disorders, Oral submucous fibrosis, Tobacco

### How to cite this Article:

Anjum A, Sheikh N. Oral Potentially Malignant Disorders: A Comprehensive Review of Diagnostic Approaches and Management Strategies. J Bahria Uni Med Dental Coll. 2024;14(1):83-9 DOI: <https://doi.org/10.51985/JBUMDC2023223>

This is an Open Access article distributed under the terms of the Creative Commons Attribution Non Commercial License (<http://creativecommons.org/licenses/by-nc/4.0>) which permits unrestricted non commercial use, distribution and reproduction in any medium, provided the original work is properly cited.

### INTRODUCTION:

Oral potentially malignant disorders (OPMDs) are a diverse group of oral conditions that have an increased risk of transforming into oral cancer if left untreated. These disorders present a significant public health concern globally. Timely diagnosis and effective management of OPMDs are crucial in reducing the risk of malignant transformation and improving patient outcomes.

In March 2020, experts gathered to discuss oral potentially malignant disorders (OPMDs), which are important precursors to oral cancer. This terminology was introduced in 2007 and has been widely adopted by healthcare professionals and researchers globally, leading to better reporting. The concept of "precancer" was introduced in 1805, suggesting that certain benign diseases could progress to invasive malignancy. The term "OPMD" replaces older terms like "precancer" and "pre-malignant." Not everyone with an OPMD will develop cancer, and cancer might not arise exactly where the OPMD was found. The presence of

OPMDs is one of many factors that increase the risk of cancer. This understanding has evolved over time, leading to better classification and management of these disorders.

Defining OPMDs is complex due to the varied nature of these disorders. They encompass a range of oral lesions and conditions that exhibit dysplastic changes or demonstrate a high potential for developing into oral cancer. Examples of OPMDs include leukoplakia, erythroplakia, oral submucous fibrosis, and oral lichen planus, among others. These disorders often share common features, such as persistent or non-healing oral lesions, changes in mucosal texture, or the presence of erythematous or white patches.

Early detection of OPMDs is of paramount importance for several reasons. Firstly, it allows for timely intervention and appropriate management strategies to be implemented, potentially preventing the progression to oral cancer. Secondly, identifying high-risk individuals with OPMDs enables targeted surveillance and follow-up, ensuring regular monitoring and timely intervention if needed. Lastly, early detection also provides an opportunity for patient education and behavioral modifications, such as tobacco cessation and lifestyle changes, which can significantly reduce the risk of malignant transformation.

Globally, oral squamous cell carcinoma (OSCC) is the most common type of oral cancer. Pakistan has a high incidence of oral cancer cases. According to Shaukat Khanum Memorial Cancer Hospital and Research Centre (SKMCH&RC), lip and oral cavity carcinomas ranked as the 3rd most common

**Angabeen Anjum** (*Corresponding Author*)  
Assistant Professor, Department of Oral Pathology,  
Baqai dental college, Baqai medical university, Karachi  
Email: [angabeen.anjum@gmail.com](mailto:angabeen.anjum@gmail.com)

**Nauman Sheikh**  
Professor and Head of Department of Oral Pathology,  
Baqai dental college, Baqai medical university, Karachi  
Email: [sheikh\\_692000@yahoo.com](mailto:sheikh_692000@yahoo.com)

Received: 17-07-2023

Accepted: 18-12-2023

malignant tumors from 1994 to 2018. OSCC is often diagnosed at a late stage with low survival rates. It frequently develops from oral potentially malignant disorders (OPMDs), chronic mucosal issues that have a higher risk of turning into cancer.

Histopathological evaluation is a cornerstone in diagnosing OPMDs, as it helps to assess the degree of dysplasia and identify any potentially malignant changes in the oral tissue. Non-invasive techniques, such as tissue fluorescence visualization and brush biopsies, have also shown promise in aiding early detection. Additionally, molecular biomarkers are being investigated to determine their potential role in predicting the risk of malignant transformation.

Imaging modalities, such as cone-beam computed tomography (CBCT) and optical coherence tomography (OCT), have gained prominence in assessing the extent and characteristics of OPMDs, providing valuable information for treatment planning. These advancements in diagnostic approaches contribute to more accurate and timely identification of OPMDs, facilitating appropriate management strategies.

The management of OPMDs involves a multidimensional approach, including accurate diagnosis, risk assessment, and appropriate therapeutic strategies. It requires collaboration between oral pathologists, oral medicine specialists, head and neck surgeons, and oncologists to ensure comprehensive care for patients with OPMDs. The goal is to determine the optimal management strategy for each individual based on the specific characteristics of their OPMD, the presence of dysplasia, and other risk factors.

The management of OPMDs involves a combination of monitoring, non-surgical interventions, and, in some cases, surgical approaches. Close surveillance of patients with OPMDs is crucial to detect any changes or signs of malignant transformation. Non-surgical interventions, such as topical treatments or systemic therapies, may be employed to manage certain OPMDs or reduce their progression.

Through this review, we seek to enhance the knowledge and understanding of healthcare professionals involved in oral pathology, ultimately contributing to the improvement of patient care and outcomes in the management of oral potentially malignant disorders.

In conclusion, oral potentially malignant disorders are a significant concern in public health, and their early detection and effective management are paramount to reduce the risk of malignant transformation. This review aims to provide healthcare professionals involved in oral pathology with comprehensive insights into the definition, classification, diagnostic approaches, and management strategies for OPMDs. By advancing our understanding and knowledge of these disorders, we can ultimately enhance patient care and outcomes in the management of oral potentially malignant disorders.

### **Risk Factors:**

Multiple risk factors have been associated with the development and progression of OPMDs. These risk factors can be categorized into modifiable and non-modifiable factors. Modifiable risk factors are those that individuals can actively address and modify to reduce their risk. Non-modifiable risk factors, on the other hand, are inherent characteristics that individuals cannot change.

1. **Tobacco Use:** Tobacco use, including smoking and smokeless tobacco, is one of the most significant risk factors for OPMDs. Both active and passive smoking have been strongly associated with an increased risk of developing OPMDs. Smokeless tobacco products, such as betel quid and areca nut, are particularly prevalent in certain regions and contribute significantly to the development of OPMDs.

2. **Alcohol Consumption:** Excessive and chronic alcohol consumption has been identified as another important risk factor for OPMDs. Alcohol acts synergistically with tobacco use, further increasing the risk of developing these disorders. Heavy alcohol consumption, especially when combined with tobacco use, has a substantial impact on the development of oral cancers.

3. **Betel Quid Chewing:** Betel quid, a mixture of betel leaf, areca nut, slaked lime, and various additives, is widely used in certain cultures, particularly in South Asia. Betel quid chewing has been strongly associated with an increased risk of developing OPMDs, including leukoplakia, submucous fibrosis, and oral cancer. The combination of areca nut and tobacco in betel quid significantly amplifies the risk.

4. **Chronic Irritation and Trauma:** Chronic irritation and trauma to the oral mucosa have been linked to the development of OPMDs. Sharp edges of broken teeth, ill-fitting dentures, and other sources of chronic friction or irritation can contribute to the formation and persistence of OPMDs. Additionally, repeated trauma from sharp or abrasive foods, toothbrushing habits, and other oral habits can also play a role.

5. **Human Papillomavirus (HPV) Infection:** Certain high-risk strains of HPV, particularly HPV-16 and HPV-18, have been associated with an increased risk of OPMDs, particularly in the oropharyngeal region. HPV-associated OPMDs often present with distinct clinical and histological features. HPV vaccination has shown promise in reducing the risk of HPV-related OPMDs.

6. **Genetic Predisposition:** Genetic factors play a role in the susceptibility to OPMDs. Certain genetic variations and polymorphisms have been identified as potential risk factors. Understanding the genetic basis of OPMDs can contribute to risk assessment and personalized management approaches.

### **Clinical Presentation of OPMDs:**

The clinical presentation of oral potentially malignant disorders (OPMDs) can vary depending on the specific

disorder and individual characteristics.

#### Common Clinical Features and Variations among Different OPMDs:

1. Leukoplakia: Leukoplakia is one of the most common OPMDs and is characterized by white or grayish patches on the oral mucosa that cannot be easily scraped off. These patches may appear flat or raised and have various textures, ranging from smooth to rough or fissured. Leukoplakia can occur on any oral surface but is commonly found on the buccal mucosa, tongue, and floor of the mouth.

2. Erythroplakia: Erythroplakia is a less common but highly significant OPMD characterized by red, velvety patches on the oral mucosa. Unlike leukoplakia, erythroplakia cannot be attributed to any specific etiological factor and has a higher potential for malignant transformation. Erythroplakic lesions often appear as smooth, well-demarcated patches and are commonly found on the floor of the mouth, tongue, or soft palate.

3. Oral Submucous Fibrosis (OSF): OSF is a chronic, progressive OPMD characterized by the development of fibrous bands in the oral mucosa, resulting in restricted mouth opening and a mottled, marble-like appearance of the oral mucosa. Individuals with OSF may experience burning sensation, difficulty in chewing, and compromised oral hygiene. OSF is strongly associated with betel quid chewing and can lead to malignant transformation.

4. Oral Lichen Planus (OLP): OLP is a chronic inflammatory OPMD that presents with characteristic lace-like white lines (Wickham's striae) on the oral mucosa. These lines may be accompanied by erythematous areas, erosions, and ulcerations. OLP can affect multiple sites in the oral cavity, including the buccal mucosa, gingiva, tongue, and palate. It is often associated with symptoms such as pain, sensitivity to certain foods, and oral discomfort.

5. Actinic Cheilitis: Actinic cheilitis is an OPMD that primarily affects the lower lip and is commonly associated with chronic sun exposure. It is characterized by dryness, cracking, and scaling of the lip vermilion. In advanced cases, ulcerations, white plaques, or induration may be observed. Actinic cheilitis has the potential for malignant transformation and requires careful evaluation and management.

#### Visual Examination and Clinical Assessment:

Visual examination of the oral cavity is a fundamental step in the diagnosis and evaluation of OPMDs.

A thorough inspection of the oral mucosa, tongue, lips, gingiva, and other oral structures should be performed. The clinician observes for any abnormal findings such as white or red patches, ulcerations, irregularities in mucosal texture, changes in color, or any other suspicious lesions.

In addition to visual examination, clinical assessment plays a crucial role in OPMD evaluation. This involves palpation

of the oral tissues to detect any induration, nodules, or masses. Clinical assessment helps determine the extent of involvement, assesses tissue consistency, and identifies areas of concern that may require further investigation or intervention.

It is important to note that the clinical presentation of OPMDs can overlap, and some lesions may exhibit more than one clinical feature. Therefore, a definitive diagnosis often requires histopathological examination through biopsy or other diagnostic procedures.

Prompt referral to an oral pathologist or specialist is recommended for a definitive diagnosis and appropriate management.

#### Diagnostic Approaches:

##### Ø Histopathological Evaluation:

Histopathological evaluation plays a crucial role in the diagnosis and assessment of oral potentially malignant disorders (OPMDs). Biopsies, obtained from suspicious lesions, are subjected to histopathological analysis to determine the presence of dysplastic changes or malignant transformation. Histopathological examination provides valuable information about the cellular characteristics, tissue architecture, and degree of dysplasia, aiding in the diagnosis, prognosis, and treatment planning for patients with OPMDs. Various grading systems, such as the World Health Organization (WHO) grading system, are utilized to classify the level of dysplasia and predict the risk of malignant transformation.

##### Ø Non-Invasive Diagnostic Techniques:

Non-invasive diagnostic techniques have gained attention in the evaluation of OPMDs, offering advantages such as simplicity, patient comfort, and the potential for repeated assessments. However, their diagnostic accuracy may be limited compared to histopathological evaluation. Oral brush cytology is a non-invasive technique that involves collecting cells from the surface of the oral mucosa for cytological analysis. While it provides a convenient method for initial screening, it has limitations in terms of sensitivity and specificity.

Salivary biomarkers have also been investigated for their potential in OPMD detection. These biomarkers include genetic, epigenetic, and protein-based markers that can be measured in saliva samples. Optical techniques such as autofluorescence, chemiluminescence, and narrow-band imaging have shown promise in enhancing the visualization of suspicious lesions and aiding in their diagnosis.

##### Ø Molecular Biomarkers:

Molecular biomarkers are emerging as valuable tools in the diagnosis and risk assessment of OPMDs. Genetic and epigenetic alterations associated with OPMDs have been extensively studied. These alterations include mutations,

deletions, and aberrant methylation patterns in specific genes involved in cell cycle regulation, DNA repair, and tumor suppression.

Molecular markers, such as p53, Ki-67, and cyclin D1, have shown potential as indicators of dysplasia and malignant transformation in OPMDs. The identification and validation of molecular biomarkers have the potential to improve diagnostic accuracy, risk stratification, and personalized management approaches for patients with OPMDs.

### Ø Imaging Modalities:

Imaging modalities play a valuable role in the diagnosis, staging, and treatment planning of OPMDs. Radiographic techniques, such as panoramic radiography and cone-beam computed tomography (CBCT), provide valuable information about the bony structures and assist in assessing the extent of the lesion, particularly in cases involving bone invasion or adjacent structures. .

Advanced imaging techniques, such as magnetic resonance imaging (MRI) and positron emission tomography (PET), offer enhanced visualization of soft tissues, enabling the detection of deep-seated or occult lesions and evaluation of regional lymph nodes. These imaging modalities aid in the comprehensive assessment of OPMDs and assist in determining the extent of the disease, facilitating appropriate treatment decisions.

### Management strategies

#### Follow-up and Surveillance Protocols:

Follow-up and surveillance protocols are crucial for individuals diagnosed with oral potentially malignant disorders (OPMDs). Risk stratification based on clinical and histopathological features helps determine the appropriate follow-up intervals and investigations. High-risk OPMDs require more frequent monitoring compared to low-risk lesions. Regular follow-up visits enable clinicians to assess the response to treatment, detect any recurrence or malignant

transformation, and provide necessary interventions in a timely manner. Recommended investigations may include visual examination, palpation, cytological or histopathological analysis, imaging studies, and assessment of salivary or molecular biomarkers.

### Non-Surgical Management:

Non-surgical management options are available for certain OPMDs, particularly those with low or moderate risk of malignant transformation. Topical medications and chemo preventive agents, such as retinoids, non-steroidal anti-inflammatory drugs (NSAIDs), and antioxidant supplements, may be prescribed to reduce inflammation, promote tissue healing, and prevent disease progression..

Laser therapy and photodynamic therapy are minimally invasive treatment modalities that can be utilized for specific cases of OPMDs. Laser therapy selectively targets and ablates abnormal tissues, while photodynamic therapy involves the administration of photosensitizing agents followed by light activation to destroy dysplastic or malignant cells.<sup>39,40</sup>

### Surgical Management:

Surgical management plays a significant role in the treatment of OPMDs, particularly for high-risk lesions or cases with confirmed dysplasia or malignancy.. Excisional and incisional biopsy techniques are employed for diagnostic purposes and removal of suspicious or dysplastic lesions. Surgical interventions, such as wide local excision, resection of involved lymph nodes, or neck dissection, may be necessary for cases with invasive carcinoma or high-risk OPMDs. The extent of surgical intervention depends on factors such as tumor size, location, depth of invasion, and regional lymph node involvement.

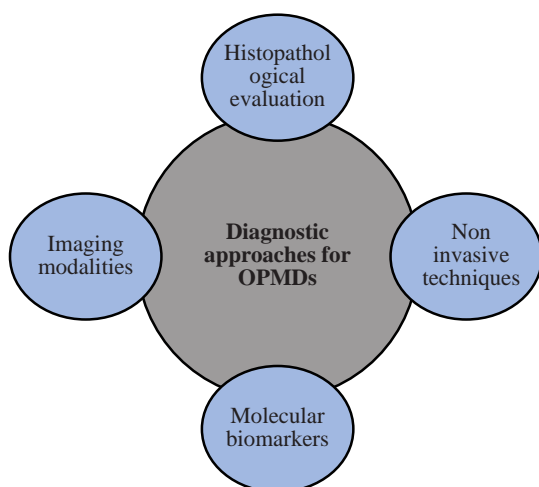
### Multidisciplinary Approaches:

Managing OPMDs often requires a multidisciplinary approach involving collaboration among oral pathologists, oral medicine specialists, oral and maxillofacial surgeons, radiation oncologists, and other healthcare professionals. This interdisciplinary collaboration ensures comprehensive evaluation, accurate diagnosis, and appropriate treatment planning. Integration of expertise from different disciplines facilitates the identification of high-risk cases, optimal selection of treatment modalities, and personalized management strategies for individuals with OPMDs. Regular tumor boards or multidisciplinary meetings can provide a platform for discussion, consensus building, and coordination of care.

### Importance of Patient Awareness and Behavior Modification:

Patient awareness is crucial in the prevention, early detection, and management of OPMDs. Educating patients about the risks associated with OPMDs, including the potential for malignant transformation, empowers them to make informed

Figure 1: Diagnostic approaches for oral potentially malignant disorders

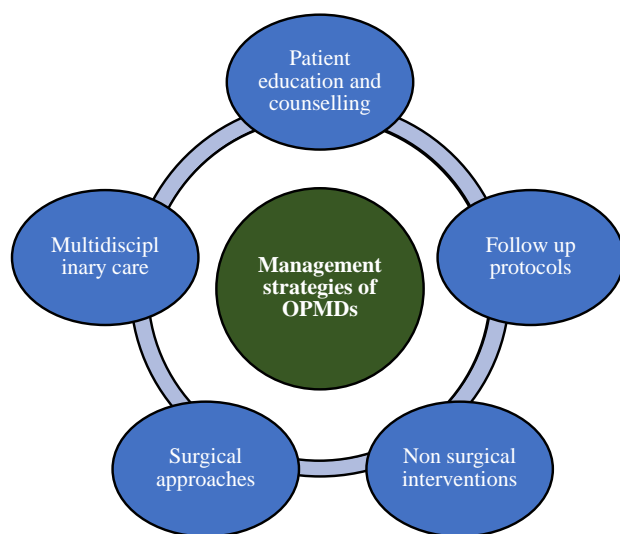




decisions about their health. It helps individuals understand the importance of regular self-examination, reporting any suspicious changes to their healthcare providers, and adhering to recommended follow-up and surveillance protocols. Patient awareness also promotes a proactive approach towards lifestyle modifications and behavior change, leading to better treatment outcomes and reduced risk of disease progression.

In summary, managing OPMDs requires a comprehensive approach that includes follow-up protocols, non-surgical and surgical interventions, multidisciplinary collaboration, patient education, and potentially incorporating lifestyle modification. The goal is to provide tailored care that addresses the individual's condition, risk factors, and treatment preferences.

Figure 2: Management strategies of OPMDs



### Future Directions and Research:

The field of oral potentially malignant disorders (OPMDs) continues to evolve, and several exciting areas of research hold promise for improving diagnostic approaches and management strategies. Two important areas of future directions and research are : novel diagnostic tools and emerging technologies, and advancements in personalized medicine and targeted therapies.

### CONCLUSION:

In conclusion, the comprehensive management of OPMDs requires early detection, risk assessment, and multidisciplinary care. Timely diagnosis through various diagnostic approaches, including histopathological evaluation, non-invasive techniques, molecular biomarkers, and imaging modalities, is crucial for accurate assessment and treatment planning. Patient education and counseling, along with targeted interventions, contribute to better treatment outcomes and overall patient well-being. By implementing these strategies, healthcare professionals can make significant strides in the effective management of oral potentially malignant disorders.

### Authors Contribution:

**Angabeen Anjum:** Manuscript conception and its preparation.

**Nauman Sheikh:** Intellectual input and critical review of manuscript

### REFERENCES

1. Warnakulasuriya S. Oral potentially malignant disorders: A comprehensive review on clinical aspects and management. *Oral oncology*. 2020;102:104550. DOI: 10.1016/j.oraloncology.2019.104550
2. Kumari P, Debta P, Dixit A. Oral potentially malignant disorders: etiology, pathogenesis, and transformation into oral cancer. *Frontiers in pharmacology*. 2022;13:825266. doi: 10.3389/fphar.2022.825266
3. Warnakulasuriya S, Kujan O, Aguirre-Urizar JM, Bagan JV, González-Moles MÁ, Kerr AR, et al. Oral potentially malignant disorders: A consensus report from an international seminar on nomenclature and classification, convened by the WHO Collaborating Centre for Oral Cancer. *Oral diseases*. 2021;27(8):1862-80. DOI: 10.1111/odi.13704
4. Parakh MK, Ulaganambi S, Ashifa N, Premkumar R, Jain AL. Oral potentially malignant disorders: clinical diagnosis and current screening aids: a narrative review. *European Journal of Cancer Prevention*. 2020;29(1):65-72. DOI: 10.1097/CEJ.0000000000000510
5. Tanriver G, Soluk Tekkesin M, Ergen O. Automated detection and classification of oral lesions using deep learning to detect oral potentially malignant disorders. *Cancers*. 2021;13(11):2766. DOI: 10.3390/cancers13112766
6. Khan AS, Ahmad S, Ullah Z, Haq M, Farooq MU, Khan M. Serum p53 antibodies detection in oral squamous cell carcinoma, oral potentially malignant disorders and healthy individuals: A multicentre study. *JPMA The Journal of the Pakistan Medical Association*. 2021;71(10):2364-8. DOI: 10.47391/JPMA.1133
7. Ranganathan K, Kavitha L. Oral epithelial dysplasia: Classifications and clinical relevance in risk assessment of oral potentially malignant disorders. *Journal of oral and maxillofacial pathology: JOMFP*. 2019;23(1):19. DOI: 10.4103/jomfp.JOMFP\_13\_19
8. DeCoro M, Wilder-Smith P. Potential of optical coherence tomography for early diagnosis of oral malignancies. *Expert review of anticancer therapy*. 2010;10(3):321-9. doi: 10.1586/era.09.191
9. Kerr AR, Lodi G. Management of oral potentially malignant disorders. *Oral Diseases*. 2021;27(8):2008-25. DOI: 10.1111/odi.13980
10. Swain SK. Premalignant lesions of the oral cavity: Current perspectives. *Int J Res Med Sci*. 2021;9:1816-22. DOI: https://doi.org/10.18203/2320-6012.ijrms20212259
11. Singh AK, Chauhan R, Anand K, Singh M, Das SR, Sinha AK. Prevalence and risk factors for oral potentially malignant disorders in Indian population. *Journal of Pharmacy & Bioallied Sciences*. 2021;13(Suppl 1):S398. doi: 10.4103/jpbs.JPBS\_751\_20
12. Lorini L, Bescós Atín C, Thavaraj S, Müller-Richter U, Alberola Ferranti M, Pamiás Romero J, et al. Overview of oral potentially malignant disorders: from risk factors to specific therapies. *Cancers*. 2021;13(15):3696. doi: 10.3390/cancers13153696.

13. Pires FR, Barreto MEZ, Nunes JGR, Carneiro NS, de Azevedo AB, dos Santos TCRB. Oral potentially malignant disorders: clinical-pathological study of 684 cases diagnosed in a Brazilian population. *Medicina Oral, Patología Oral y Cirugía Bucal*. 2020;25(1):e84. DOI: 10.4317/medoral.23197
14. Reddy DI, Narayana ML, Viswambharan V, Chaithanya NR. Betel quid and tobacco chewing habits and its associated clinical findings in a rural tertiary care hospital. *International Journal of Otorhinolaryngology and Head and Neck Surgery*. 2020;6(4):732. DOI: <https://doi.org/10.18203/issn.2454-5929.ijohns20201291>
15. Pentenero M, Azzi L, Lodi G, Manfredi M, Varoni E. Chronic mechanical trauma/irritation and oral carcinoma: A systematic review showing low evidence to support an association. *Oral diseases*. 2022;28(8):2110-8. DOI: 10.1111/odi.14049
16. Sri S, Ramani P, Premkumar P, Ramshankar V, Ramasubramanian A, Krishnan RP. Prevalence of Human Papillomavirus (HPV) 16 and 18 in oral malignant and potentially malignant disorders: A polymerase chain reaction analysis—A comparative study. *Annals of Maxillofacial Surgery*. 2021;11(1):doi: 10.4103/ams.ams\_376\_20
17. Shridhar K, Aggarwal A, Walia GK, Gulati S, Geetha A, Prabhakaran D, et al. Single nucleotide polymorphisms as markers of genetic susceptibility for oral potentially malignant disorders risk: Review of evidence to date. *Oral Oncology*. 2016;61:146-51. DOI: 10.1016/j.oraloncology.2016.08.005
18. Iocca O, Sollecito TP, Alawi F, Weinstein GS, Newman JG, De Virgilio A, et al. Potentially malignant disorders of the oral cavity and oral dysplasia: A systematic review and meta-analysis of malignant transformation rate by subtype. *Head & neck*. 2020;42(3):539-55. DOI: 10.1002/hed.26006
19. Carrard VC, Van der Waal I. A clinical diagnosis of oral leukoplakia; A guide for dentists. *Medicina oral, patología oral y cirugía bucal*. 2018;23(1):e59. DOI: 10.4317/medoral.22292
20. Warnakulasuriya S. Clinical features and presentation of oral potentially malignant disorders. *Oral surgery, oral medicine, oral pathology and oral radiology*. 2018;125(6):582-90. DOI: 10.1016/j.oooo.2018.03.011
21. Rao NR, Villa A, More CB, Jayasinghe RD, Kerr AR, Johnson NW. Oral submucous fibrosis: a contemporary narrative review with a proposed inter-professional approach for an early diagnosis and clinical management. *Journal of Otolaryngology-Head & Neck Surgery*. 2020;49(1):1-11. DOI: 10.1186/s40463-020-0399-7
22. Shih Y-H, Wang T-H, Shieh T-M, Tseng Y-H. Oral submucous fibrosis: a review on etiopathogenesis, diagnosis, and therapy. *International journal of molecular sciences*. 2019;20(12):2940. doi: 10.3390/ijms20122940
23. González-Moles MÁ, Warnakulasuriya S, González-Ruiz I, González-Ruiz L, Ayen A, Lenouvel D, et al. Worldwide prevalence of oral lichen planus: A systematic review and meta-analysis. *Oral diseases*. 2021;27(4):813-28. DOI: 10.1111/odi.13323
24. Vasilovici A, Ungureanu L, Grigore L, Cojocaru E, ăenilă S. Actinic Cheilitis—From Risk Factors to Therapy. *Frontiers in Medicine*. 2022;9:805425.doi.org/ 10.3389/fmed.2 022.805425
25. Walsh T, Warnakulasuriya S, Lingen MW, Kerr AR, Ogden GR, Glenny A-M, et al. Clinical assessment for the detection of oral cavity cancer and potentially malignant disorders in apparently healthy adults. *Cochrane Database of Systematic Reviews*. 2021(12). DOI: 10.1002/14651858.CD010173.pub3
26. Gaddikeri K. Clinical-pathological Study Of Patients With Oral Potentially Malignant Disorders. *Int J Acad Med Pharm*. 2023;5(3):609-15. DOI: 10.47009/jamp.2023.5.3.127
27. Abdul NS. Role of Advanced Diagnostic Aids in the Detection of Potentially Malignant Disorders and Oral Cancer at an Early Stage. *Cureus*. 2023;15(1). doi: 10.7759/cureus.34113
28. Odell E, Kujan O, Warnakulasuriya S, Sloan P. Oral epithelial dysplasia: recognition, grading and clinical significance. *Oral diseases*. 2021;27(8):1947-76. DOI: 10.1111/odi.13993
29. Kim DH, Kim SW, Hwang SH. Efficacy of non-invasive diagnostic methods in the diagnosis and screening of oral cancer and precancer. *Brazilian Journal of Otorhinolaryngology*. 2022;88:937-47. DOI: 10.1016/j. bjourl.2020.12.019
30. H. Alsarraf A, Kujan O, Farah CS. The utility of oral brush cytology in the early detection of oral cancer and oral potentially malignant disorders: A systematic review. *Journal of Oral Pathology & Medicine*. 2018;47(2):104-16. DOI: 10.1111/jop.12660
31. Piayathne NS, Rasnayake R, Angammana R, Chandrasekera P, Ramachandra S, Weerasekera M, et al. Diagnostic salivary biomarkers in oral cancer and oral potentially malignant disorders and their relationships to risk factors—A systematic review. *Expert Review of Molecular Diagnostics*. 2021;21(8):789-807. DOI: 10.1080/14737159.2021.1944106
32. Shin D, Vigneswaran N, Gillenwater A, Richards-Kortum R. Advances in fluorescence imaging techniques to detect oral cancer and its precursors. *Future oncology*. 2010;6(7):1143-54. DOI: 10.2217/fon.10.79
33. Yap T, Celentano A, Seers C, McCullough MJ, Farah CS. Molecular diagnostics in oral cancer and oral potentially malignant disorders—A clinician's guide. *Journal of Oral Pathology & Medicine*. 2020;49(1):1-8. DOI: 10.1111/jop.12920
34. Ranganath K, Feng AL, Franco RA, Varvares MA, Faquin WC, Naunheim MR, et al. Molecular Biomarkers of Malignant Transformation in Head and Neck Dysplasia. *Cancers*. 2022;14(22):5581.doi.org/10.3390/cancers14225581
35. Ilhan B, Lin K, Guneri P, Wilder-Smith P. Improving oral cancer outcomes with imaging and artificial intelligence. *Journal of dental research*. 2020;99(3):241-8. DOI: 10.1177/0022034520902128
36. El Kininy W, Israr M, Toner M, Meaney J, Stassen L. Prospective Comparison of CT scan, MRI and PET/CT in the Diagnosis of Oral Cancer and Nodal Metastasis. *Int J Surg Res Pract*. 2017; 4:050. DOI: 10.23937/2378-3397/1410050
37. Jäwert F, Nyman J, Olsson E, Adok C, Helmersson M, Öhman J. Regular clinical follow-up of oral potentially malignant disorders results in improved survival for patients who develop oral cancer. *Oral oncology*. 2021;121:105469. DOI: 10.1016/j.oraloncology.2021.105469
38. Borse V, Konwar AN, Buragohain P. Oral cancer diagnosis and perspectives in India. *Sensors International*. 2020;1:100046. doi: 10.1016/j.sintl.2020.100046

39. Kundoor VKR, Patimeedi A, Roohi S, Maloth KN, Kesidi S, Masabattula GK. Efficacy of diode laser for the management of potentially malignant disorders. *Journal of lasers in medical sciences*. 2015;6(3):120. DOI: 10.15171/jlms.2015.05
40. Binnal A, Tadakamadla J, Rajesh G, Tadakamadla SK. Photodynamic therapy for oral potentially malignant disorders: A systematic review and meta-analysis. *Photodiagnosis and Photodynamic Therapy*. 2022;37:102713. DOI: 10.1016/j.pdpdt.2022.102713
41. Awadallah M, Idle M, Patel K, Kademani D. Management update of potentially premalignant oral epithelial lesions. *Oral surgery, oral medicine, oral pathology and oral radiology*. 2018;125(6):628-36. DOI: 10.1016/j.oooo.2018.03.010
42. Paderno A, Bossi P, Piazza C. Advances in the Multidisciplinary Management of Oral Cancer. *Frontiers in Oncology*. 2021; 11:817756.doi.org/10.3389/fonc.2021.817756
43. Lin H-J, Wang X-L, Tian M-Y, Li X-L, Tan H-Z. Betel quid chewing and oral potential malignant disorders and the impact of smoking and drinking: A meta-analysis. *World Journal of Clinical Cases*. 2022;10(10):3131 doi: 10.12998/wjcc.v10.i10.3131
44. Dionne KR, Warnakulasuriya S, Binti Zain R, Cheong SC. Potentially malignant disorders of the oral cavity: Current practice and future directions in the clinic and laboratory. *International journal of cancer*. 2015;136(3):503-15. DOI: 10.1055/s-0042-1756663