

## Evaluation of Brain MRI in Cerebral Palsy Patients in the Children's Hospital Lahore

Saba Fatima, Amber Goraya, Hina Azhar, Abid Ali Qureshi

### ABSTRACT:

**Objective:** Evaluation of brain MRI findings in Cerebral Palsy patients and categorization according to MRICS.

**Study design and settings:** Descriptive case series and Department of Pediatric Radiology, UCHS and The Children's Hospital Lahore.

**Methodology:** 57 patients fulfilling inclusion criteria of clinical diagnosis of Cerebral Palsy were included in the study over a period of 3 months from 1st January 2021 to 31<sup>st</sup> March 2021. 4 patients were not included because of no to poor sedation. After written informed consent, MRI brain was conducted on these patients. The scans were then interpreted by Pediatric Radiologists and were further categorized using MRICS. Statistical analysis was done using SPSS 24.

**Results:** There were 53 patients with age range from 2-13 years with 33 males and 20 females. Predominant white matter injury (58.5%) was most common and Predominant gray matter injury (11%) was next common. Maldevelopment was the rarest pattern only found in 3.8% patients. Normal MRI were noted with no imaging evidence of brain injury in 5 patients. On further categorization of the MRI patterns, Periventricular leukomalacia was most frequent pattern followed by Multicystic encephalomalacia.

**Conclusion:** Considering less frequency of normal MRI brain, this study concluded that MRI brain is helpful in diagnosing Cerebral Palsy and MRICS is a good qualitative method of categorization of brain injury patterns.

**Key Words:** Cerebral Palsy, Encephalomalacia, Leucomalacia, MRICS, Neuroimaging.

### How to cite this Article:

Fatima S, Goraya A, Azhar H, Qureshi AA, Fatima S, Goraya A, Azhar H, Qureshi AA. Evaluation of Brain MRI in Cerebral Palsy Patients in the Children's Hospital Lahore. J Bahria Uni Med Dental Coll. 2024;14(1):40-4 DOI: <https://doi.org/10.51985/JBUMDC2023231>

This is an Open Access article distributed under the terms of the Creative Commons Attribution Non Commercial License (<http://creativecommons.org/licenses/by-nc/4.0>) which permits unrestricted non commercial use, distribution and reproduction in any medium, provided the original work is properly cited.

### INTRODUCTION:

Cerebral palsy is a group of developmental disorders of movement and posture which result in activity limitation. It is a common cause of motor disability in children and is caused by non progressive disturbances to developing/immature brain.<sup>1</sup> It has a prevalence of approximately 1 in 500 live births and incidence of 2-2.5 per 1000 live births with estimated 17 million people being affected globally.<sup>2,3</sup> Underlying etiologies for cerebral palsy is complex with

multiple types of antenatal, natal and post-natal risk factors associated with it. Congenital brain malformations, vascular injuries, maternal infections and metabolic disorders are among common antenatal causes of Cerebral Palsy. Problems during labor and delivery as well as in immediate post birth period contribute to perinatal risk of developing CP. Post neonatal acquired cerebral palsy is commonly caused by infections and trauma.<sup>4</sup>

Along with detailed history and physical examination, neuroimaging with MRI brain is an important part of clinical evaluation of CP patients. It has been proved that MRI brain demonstrates abnormalities in almost more than 80% of the patients.<sup>5,6</sup> Neuroimaging helps in assessment of neuroanatomical basis for function in cerebral palsy along with underlying pathogenic pattern and normal structure function relationship. The resulting impairments relate to the timing of brain injury and development of typical brain lesions which can be assessed using MRI brain.<sup>7</sup> MRI Classification System (MRICS) was devised as a reliable tool in assessment of CP by Surveillance of Cerebral Palsy in Europe (SCPE) in 2016.<sup>8</sup> This system is based on occurrence of pathogenic patterns according to different brain development periods as different causes can lead to same imaging manifestations. Therefore, MRICS used a standardized approach for description of pathogenic and imaging patterns in relation to timing of injury rather than

#### Saba Fatima

Senior Registrar, Department of Pediatric Radiology  
Sir Ganga Ram Hospital, Lahore  
Email: sabaazhar.23@gmail.com

#### Amber Goraya

Associate Professor, Department of Pediatric Radiology,  
UCHS and The Children's Hospital Lahore  
Email: amber.goraya@yahoo.com

#### Hina Azhar

Assistant Professor, Department of Developmental Pediatrics  
UCHS and The Children's Hospital Lahore  
Email: hinaazhar2009@gmail.com

#### Abid Ali Qureshi

Professor and Head, Department of Pediatric Radiology,  
UCHS and The Children's Hospital Lahore  
Email: abidaliqureshi67@gmail.com

Received: 01-08-2023

Accepted: 29-12-2023

using etiology as classification basis. It consists of mainly five groups: maldevelopments, white matter injury, grey matter injury, miscellaneous and normal findings.<sup>8</sup> Several studies have been done in past to describe various MRI patterns of pathologic process in brain. 213 children were assessed by MRI in 2011 and documented cerebral abnormalities in 87% of study population. Periventricular white matter injury was found to be the most common imaging pattern followed by grey matter injury and maldevelopments.<sup>9</sup> Likewise another study in India also concluded that 89% study population had abnormal MRI. Periventricular white matter injury was concluded as the commonest finding in CP followed by focal vascular lesions and brain malformations.<sup>10</sup> However, a Turkish hospital based study revealed cerebral atrophy to be the most common pattern followed by periventricular leukomalacia with the least common imaging manifestation being congenital brain malformation.<sup>11</sup>

Considering non availability of any research related to imaging evaluation of CP patients in Pakistan, the rationale of this study is to describe and analyze various patterns of MRI brain according to MRICS which may help in clinical correlation and planning of rehabilitation services for these patients. Extent of brain injury will also help in determining prognosis and counselling their parents regarding the future outcomes. Moreover, identification of normal MRI findings will also help in establishing strong evidence for non requirement of neuroimaging and thus may reduce the burden of unnecessary investigations in children with cerebral palsy.

#### METHODOLOGY:

After approval from the ethical review committee of Children's Hospital and Institute of Child Health (ERC no 2021-260-CHICH), total 57 patients were enrolled in Department of Pediatric Radiology, The Children Hospital and Institute of Child Health, Lahore. These patients were selected based on fulfilling the inclusion criteria (aged 2 to 18 years with clinical diagnosis of CP) and excluding those with congenital syndromes and degenerative brain disease. Sample size was calculated using formula  $n = Z^2 p (1-p) / e^2$  and sample was drawn using non probability consecutive sampling.

4 patients could not be sedated properly (which is the requirement for brain MRI) and hence were not included for study. An informed written consent was taken from each patient/parent and the study was conducted in duration of 3 months from 1<sup>st</sup> January 2021 to 31<sup>st</sup> March 2021. MRI brain was performed on 1.5 T machine (Philips Medical Systems Nederland B.V.) using standard protocols. The standard brain MRI protocol included T1W (TE 15, TR 581), T2W (TE 110, TR 5212) and FLAIR (TE 120, TR 12000, TI 25) sequences in sagittal, axial and coronal planes. These scans were then reported by 3 pediatric Radiologists

who were blinded to clinical details of the patients. The scans were interpreted and classified into 5 major categories according to MRICS.<sup>8</sup> Further subtypes were also documented according to same system (Table 1).

**Statistical Analysis:** The collected data was entered and analyzed by using SPSS version 24.0. Mean and standard deviation was calculated for numerical variables like age. Frequency and percentages were calculated for categorical variables like gender, various MRI patterns of brain injury according to MRICS along with their subcategories.

#### RESULTS:

This study was conducted on 53 patients ranging in age from 2-13 years with median age of 5.5 years  $\pm$  2.7 years (Table 2). There were 20 females (37.7%) and 33 males (62.3%). The most frequent imaging pattern according to MRICS was predominant WM injury found in 58.5% of patients followed by predominant GM injury found in 17% of patients. (Fig 1).

**A. MALDEVELOPMENTS:** It was the least found pattern with only 2 patients having migration anomalies (A.1). These patients showed Pachygyria as broadened thickened gyri on MRI brain scans. No cases were found of other maldevelopments (A.2) like holoprosencephaly, corpus callosum agenesis or Dandy Walker malformation.

**B. PREDOMINANT WHITE MATTER INJURY:** It was the most commonly found pattern in this study in 31 patients. All patients showed PVL--Periventricular Leukomalacia (B.1). It was documented as signal changes in periventricular white matter more marked in posterior and peritrigonal regions. These signal changes appeared as T2W and FLAIR hyperintense areas (Fig 2). There were no patients found of IVH--Intraventricular Hemorrhage (B.2) or a combination of both PVL and IVH (B.3).

**C. PREDOMINANT GRAY MATTER INJURY:** 9 patients displayed predominant gray matter injury pattern. 11% patients had involvement of basal ganglia and thalamic nuclei (C.1.). Involved areas of brain demonstrated hyperintense signals on both T2W and FLAIR images. Further encephalomalacic changes (C.2.) in form of multiple areas of fluid/CSF signal intensity were also noted in this group in 17% of study population (Fig 3). No patient had arterial infarctions on brain MRI (C.3.).

**D. MISCELLANEOUS:** There were only 6 patients who showed isolated miscellaneous pattern of brain injury as the predominant MRICS finding. Majority of the patients showed miscellaneous findings in association with other predominant injury patterns. Cerebral atrophy was the commonest miscellaneous pattern found in study population in 13% patients with diffuse brain atrophy found in 9% of patients. Less commonly found patterns were isolated cerebellar atrophy, ventriculomegaly and brain stem lesions each found in 1 patient only.

**E. NORMAL:** There were 5 patients who did not show any abnormal imaging pattern.

**SUBCATEGOTRIES OF MRICS:** Upon further sub categorization, Periventricular Leukomalacia (PVL) was

Fig 1. Frequency of various MRICS patterns

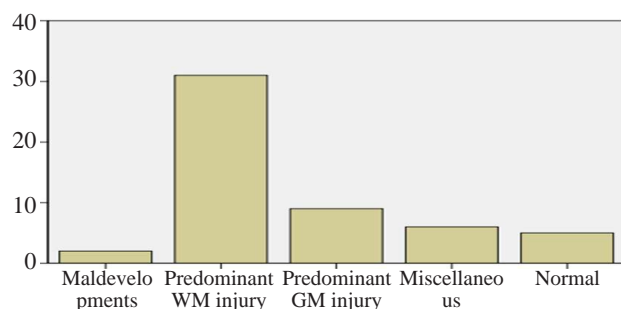
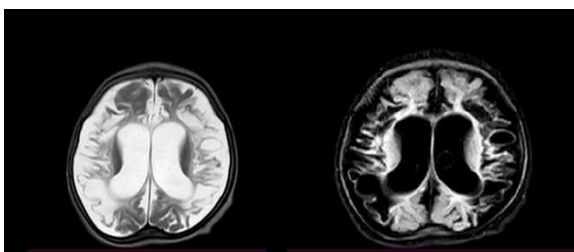


Figure 2. T2W and FLAIR images showing bilateral periventricular white matter hyperintensities ---Predominant White Matter Injury

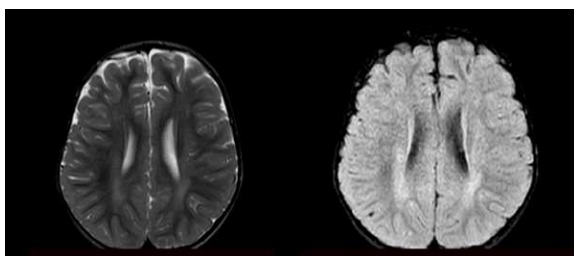

Figure 3. T2W and FLAIR images showing multicystic Encephalomalacia in bilateral frontoparietal lobes with brain atrophy



the commonest imaging finding followed by multicystic encephalomalacia changes found in 67 and 17% patients respectively.

## DISCUSSION:

Cerebral palsy covers a group of developmental disorders of movement and posture with resultant limited activity, caused by non progressive disturbances to developing/immature brain.<sup>1</sup> There are various types of causative and risk factors associated with development of Cerebral Palsy which can lead to variable patterns of brain injury. These patterns are more strongly correlated to the timing of brain injury rather than the etiological factor.<sup>4</sup>

Neuroimaging with MRI brain helps in identifying underlying pathogenic patterns in more than 80% of the patients.<sup>5,6</sup> Injury to the developing brain results in various imaging patterns on MRI which were qualitatively classified by Surveillance of Cerebral Palsy in Europe (SCPE) in 2016 as MRI Classification System (MRICS). MRICS used a standardized approach for imaging classification based upon timing of brain insult or injury which is more specific than the causative factor.<sup>6</sup> Usefulness of MRICS was studied in a Hungarian cohort of 257 patients which documented positive MRI findings in 86.4% of patients with normal scans in 13.6% patients.<sup>6</sup> Our study also showed positive MRI findings in 90.6% of patients with only 9.4% normal scans in agreement with results of studies performed in Turkey and Europe.<sup>11,12</sup> The Turkish cohort study proved that MRI brain scans were positive for 92.7% study population with only 7.3% normal MRI scans<sup>11</sup> while European cross sectional study concluded positive MRI scans in 88.3% patients and 11.7% normal scans.<sup>12</sup>

Various MRICS patterns are known to cause cerebral palsy with varying degrees of severity. In this study, predominant white matter injury was the most common pattern found in 58.5% patients, followed by gray matter injury in 17% and miscellaneous patterns in 11%. These frequencies are in

Table 1. MRI classification system proposed by the SCPE network<sup>8</sup>

A. Maldevelopments
A.1. Disorders of cortical formation (proliferation and/or migration and/or organization)
A.2. Other maldevelopments (examples: holoprosencephaly, Dandy-Walker malformation, corpus callosum agenesis, cerebellar hypoplasia)
B. Predominant white matter injury
B.1. PVL (mild/severe)
B.2. Sequelae of IVH or periventricular haemorrhagic infarction
B.3. Combination of PVL and IVH sequelae
C. Predominant grey matter injury
C.1. Basal ganglia/thalamus lesions (mild/moderate/severe)
C.2. Cortico-subcortical lesions only (watershed lesions in parasagittal distribution/multicystic encephalomalacia) not covered under C3
C.3. Arterial infarctions (middle cerebral artery/other)
D. Miscellaneous (examples: cerebellar atrophy, cerebral atrophy, delayed myelination, ventriculomegaly not covered under B, haemorrhage not covered under B, brainstem lesions, calcifications)
E. Normal

Table 2. Distribution of study population according to age

Age	Frequency	Percentage
2.00	1	1.9
2.50	1	1.9
3.00	13	24.5
4.00	6	11.3
4.50	1	1.9
5.00	8	15.1
5.10	1	1.9
6.00	7	13.2
6.10	1	1.9
7.00	5	9.4
8.00	3	5.7
9.00	1	1.9
11.00	1	1.9
12.00	1	1.9
13.00	3	5.7
Total	53	100.0

contrast to previous studies where maldevelopments also contributed to a significant number of brain injury patterns.

Surveillance of cerebral palsy in Europe (SCPE) who devised MRICS analyzed MRI scans of 3818 children from 18 European countries. SCPE concluded white matter injury to be most frequent MRICS pattern in 49% patients followed by predominant gray matter injury and maldevelopments in 21 and 11 % of cases respectively.<sup>12</sup> A Hungarian cohort study used MRICS and proved white matter injury in 35.4% patients followed by maldevelopments and gray matter injuries in 18% each while 12.5% patients showed miscellaneous pattern of brain injury.<sup>13</sup> A large cohort group study performed in Sweden proved white matter injury pattern to be found in 48.7%, gray matter injury pattern in 21%, maldevelopments in 11 % with miscellaneous lesions in only 8.5%.<sup>14</sup> Results of this study were in contradiction to previous data in terms of frequency of maldevelopments as the study population only demonstrated changes in 3.8 % of patients.

Further subcategories of major injury patterns were also documented using MRICS. The most common predominant white matter injury was Periventricular leukomalacia found in 36 patients (67.9%) in accordance with previous data in literature. Predominant gray matter injury was the second most common pattern according to MRICS. Two further subcategories were identified with cortical/ subcortical/ multicystic encephalomalacia being more common in 17% and thalamic/basal ganglia lesions in 11% of study population. Miscellaneous pattern of brain injury was found in 11% of population which was in accordance with previous results. Further categorization of miscellaneous lesions was also documented and it proved cerebral atrophy to be found in 13% of the patients showing positive miscellaneous findings.

Cerebellar atrophy, delayed myelination, brainstem lesions and ventriculomegaly in sub categorization were very rare and found in 1 patient each.

Two cohort studies performed in Australia proved that periventricular white matter injury is the most common MRI pattern in CP patients found in 45% and 31% patients. These were followed by gray matter injury (14%), Brain malformations (12%) and miscellaneous patterns(7%).<sup>15,16</sup> A Turkish cohort showed PVL as the commonest finding in 33% patients followed by cerebral atrophy (12.9%), migration anomaly (9.7%), cerebellar involvement (3.2%) and basal ganglion involvement in 4 cases (6.4%).<sup>17</sup> Our study results were in accordance with this published data except brain malformations which were found to be rare in our study population. A south African study concluded basal ganglion lesions as most frequent in 27.6% study population however PVL and cystic encephalomalacia were found in only 3.6 and 7.8% patients respectively.<sup>18</sup> A Pakistani cross sectional analysis revealed cerebral atrophy as the commonest imaging manifestation found in 40.5% patients while PVL was only found in 5.4% population.<sup>19</sup> Our study results were contradictory to these literature observations in terms of frequency of all brain imaging patterns. Two Bengali studies performed in tertiary care hospitals showed decreased frequency of PVL in MRI patterns as compared to other abnormalities found in only 20 and 25% of patients in contrast to our study. Multicystic encephalomalacia and basal ganglia lesions are found in 19.3 and 11.4% cases in one of these studies while the frequency of cortical and deep gray matter lesions was found to be 48.5% in other study which was not in accordance with our results. Among the miscellaneous patterns, cerebral atrophy was noted in 34% and ventriculomegaly in 14.8% study population of these studies which were more frequent than our study results. However, brain maldevelopments were found in only 5% of the population in these studies which supported our study results of 3.8%.<sup>20,21</sup>

**FUTURE PERSPECTIVES FOR CP:** In our study, there were 9.4% of patients who had clinical diagnosis of cerebral palsy however their MRI brain scans were normal according to MRICS categorization. Such patients with atypical clinical presentations should be considered for further genetic evaluation. Genetic work up must be done in a systematic approach in order to increase the diagnostic yield with special importance given to treatable causes as well as reducing the cost of these genetic tests. This will help in identifying possible treatment options, possibilities of inheritance and also for family planning if considered appropriate.<sup>22</sup>

**STRENGTH AND LIMITATIONS OF STUDY:** the main strength of this study is that it used a standardized method of categorization of imaging findings using MRICS. The limitations of the study included that the data set was relatively small and there were no clinical correlates included



for this study which could help in further assessment of these patients.

## CONCLUSION:

Cerebral Palsy being investigated by MRI brain helps in assessment of brain injury pattern successfully. By using MRICS, this study concluded predominant WM injury as the most frequent pattern of brain injury in accordance with previous international literature. Likewise other categories of MRICS had similar frequencies except Maldevelopments which were found to be more common internationally as compared to this study population. Having a very low population with normal MRI brain, this study is strongly conclusive for use of MRI brain in clinical evaluation of CP patients.

### Authors Contribution:

**Saba Fatima:** Concerned with concept, data collection, analysis and article writing

**Amber Goraya:** Concerned with concept, data collection, analysis and article writing

**Hina Azhar:** Concerned with review of article

**Abid Ali Qureshi:** Concerned with review of article

## REFERENCES:

- Rosenbaum P, Paneth N, Leviton A, Goldstein M, Bax M, Damiano D, Dan B, Jacobsson B. A report: the definition and classification of cerebral palsy April 2006. *Dev Med Child Neurol Suppl.* 2007;109:8-14.
- Schiariti V, Longo E, Shoshmin A, Kozhushko L, Besstrashnova Y, Król M, Neri Correia Campos T, Náryma Confessor Ferreira H, Verissimo C, Shaba D, Mwale M. Implementation of the International Classification of Functioning, Disability, and Health (ICF) core sets for children and youth with cerebral palsy: global initiatives promoting optimal functioning. *Int J Environ Res Public Health.* 2018;15(9):1899. <https://doi.org/10.3390/ijerph15091899>
- Rosenbaum P, Rosenbloom L. *Cerebral palsy: From diagnosis to adult life.* London: Mac Keith Press; 2012.
- Reddihough DS, Collins KJ. The epidemiology and causes of cerebral palsy. *Aust J Physiother.* 2003;49(1):7-12. [https://doi.org/10.1016/S0004-9514\(14\)60183-5](https://doi.org/10.1016/S0004-9514(14)60183-5)
- Reid SM, Dagia CD, Ditchfield MR, Carlin JB, Reddihough DS. Population-based studies of brain imaging patterns in cerebral palsy. *Dev Med Child Neurol.* 2014;56(3):222-32. <https://doi.org/10.1111/dmcn.12228>
- Nagy E, Herbert Z, Péter I, Csorba E, Skobrák A, Farkas N, Hollódy K. The usefulness of MRI Classification System (MRICS) in a cerebral palsy cohort. *Acta Paediatr.* 2020. <https://doi.org/10.1111/apa.15280>
- Himmelmann K, Uvebrant P. Function and neuroimaging in cerebral palsy: a population-based study. *Dev Med Child Neurol.* 2011;53(6):516-21. <https://doi.org/10.1111/j.1469-8749.2011.03932>
- Himmelmann K, Horber V, De La Cruz J, Horridge K, Mejaski-Bosnjak V, Hollódy K, Krägeloh-Mann I, SCPE Working Group, Cans C, Bakel V, Arnaud C. MRI classification system (MRICS) for children with cerebral palsy: development, reliability, and recommendations. *Dev Med Child Neurol.* 2017;59(1):57-64.
- Towsley K, Shevell MI, Dagenais L, Repacq Consortium. Population-based study of neuroimaging findings in children with cerebral palsy. *Eur J Paediatr Neurol.* 2011;15(1):29-35. <https://doi.org/10.1016/j.ejpn.2010.07.005>
- Prasad R, Verma N, Srivastava A, Das BK, Mishra OP. Magnetic resonance imaging, risk factors and co-morbidities in children with cerebral palsy. *J. Neurol.* 2011;258(3):471-8.
- Ali A, Yalçın R, Ünlüer-Gümü\*ta° A. Cranial MR characteristics of Cerebral Palsy cases and correlation of findings with clinical results. *Turk J Pediatr.* 2019;61(4). DOI: 10.24953/turkjped.2019.04.009
- Bax M, Tydeman C, Flodmark O. Clinical and MRI correlates of cerebral palsy: the European Cerebral Palsy Study. *J Am Med Assoc.* 2006;296(13):1602-8. doi:10.1001/jama.296.13.1602
- Horber V, Sellier E, Horridge K, Rackauskaite G, Andersen GL, Virella D, Ortibus E, Dakovic I, Hensey O, Radsel A, Papavasiliou A. The origin of the cerebral palsies: contribution of population-based neuroimaging data. *Neuropediatrics.* 2020;51(02):113-9. DOI: 10.1055/s-0039-3402007
- Himmelmann K, Horber V, Sellier E, De la Cruz J, Papavasiliou A, Krägeloh-Mann I. Neuroimaging Patterns and Function in Cerebral Palsy—Application of an MRI Classification. *Front Neurol.* 2021;11:1889. <https://doi.org/10.3389/fneur.2020.617740>
- Reid SM, Dagia CD, Ditchfield MR, Carlin JB, Meehan EM, Reddihough DS. An Australian population study of factors associated with MRI patterns in cerebral palsy. *Dev Med Child Neurol.* 2014;56(2):178-84. <https://doi.org/10.1111/dmcn.12331>
- Robinson MN, Peake LJ, Ditchfield MR, Reid SM, Lanigan A, Reddihough DS. Magnetic resonance imaging findings in a population-based cohort of children with cerebral palsy. *Dev Med Child Neurol.* 2009;51(1):39-45. <https://doi.org/10.1111/j.1469-8749.2008.03127.x>
- Đik N, Öztekyń Ö, SarioĐlu FC, SarioĐlu B. Evaluation of the relationship between cranial magnetic resonance imaging findings and clinical status in children with cerebral palsy. *Turk J Med Sci.* 2021. DOI 10.3906/sag-2010-187
- Elsingery MM, Worede F, Venkatakrishna S, Curic J, Andronikou S. Magnetic resonance imaging diagnosis of causes of cerebral palsy in a developing country: A database of South African children. *S Afr Med J.* 2021;111(9):910-6. <https://doi.org/10.7196/SAMJ.2021.v111i9.15666>
- Khan SA, Talat S, Malik MI. Risk factors, types, and neuroimaging findings in Children with Cerebral Palsy. *Pak J Med Sci.* 2022;38(7):1738. doi: <https://doi.org/10.12669/pjms.38.7.6175>
- Nabi N, Shefa J, Akhter S. Neuro-imaging findings in children with developmental delay and cerebral palsy: experience from a tertiary medical center of Bangladesh. *BIRDEM Med J.* 2021;11(2):112-5.